



QUALITY ANALYSIS OF FOUR FILLING TECHNIQUES IN OVOID ROOT CANALS PREPARED WITH M® INSTRUMENTS

Luara Rech ¹, Fabiana Soares Grecca ², Tiago André Fontoura de Melo ³

¹ Undergraduate Student, Dentistry College, Universidade Federal do Rio Grande do Sul – Porto Alegre, RS, Brazil.

² Titular Professor, Endodontic Division, Department of Conservative Dentistry, Universidade Federal do Rio Grande do Sul – Porto Alegre, RS, Brazil.

³ Assistant Professor, Endodontic Division, Department of Conservative Dentistry, Universidade Federal do Rio Grande do Sul – Porto Alegre, RS, Brazil.

CORRESPONDING AUTHOR: tiago.melo@ufrgs.br

ABSTRACT

Aims: This study assessed the quality of four filling techniques in oval root canals pre-pared using M® instruments.

Materials and Methods: Sixty oval root canals underwent endodontic treatment with M® instruments and were subsequently divided randomly into four experimental groups, each employ-ing a different obturation technique: TU - single cone; TL - cold lateral compaction; TH - Tagger’s hybrid technique; TS – Schilder’s technique. Digital radiographs were taken in mesiodistal and buccolingual directions to examine the filled teeth. The percentage of filling material and empty spaces was quantified using Photoshop® software. Data were subjected to statistical analysis using the one-way ANOVA test and T-test ($\alpha = 0.05$).

Results: TL and TS presented fewer unfilled areas than TU and TH groups ($P < 0.0001$). When the radiographic directions were assessed, the mesiodistal view in TU and TL groups exhibited a higher percentage of unfilled spaces than the buccolingual view ($P < 0.05$).

Conclusions: Cold lateral compaction and Schilder’s techniques demonstrated superior perfor-mance in effectively filling oval root canals.

KEYWORDS: Endodontics. Root canal obturation. Dental pulp cavity. Radiography dental. Sealing quality.
<https://doi.org/10.59306/jrd.v12e1202423-28>

INTRODUCTION

Cleaning, preparing, and ensuring a hermetic seal of the root canal system are widely recognized as essential steps for achieving successful endodontic treatment^{1,2}.

With rotary nickel-titanium (NiTi) instruments, gutta-percha cones designed to match their conformation and taper were introduced to the

dental market. More recently, Easy has launched manual NiTi Instrument M® and their corresponding gutta-percha cones. These products are primarily aimed at undergraduate students and general practitioner dentists. A study by Silva et al.³ (2022) reported positive outcomes regarding including ProDesign M® instruments in undergraduate teaching. The study

found high satisfaction levels among professors and students and improved teaching and learning processes. The NiTi manual instrument is intended to make endodontic preparation safer and more efficient than traditional stainless-steel instruments. In an analysis comparing ProDesign M® and Flexofile instruments, Zarpelon et al.⁴ (2018) observed that Flexofile

Table 1. Demonstrative table of experimental groups.

Groups	n	Obturation Technique
TU	15	Single cone
TL	15	Cold lateral condensation
TH	15	Tagger's hybrid technique
TS	15	Schilder's technique

instruments did not offer sufficient capacity to maintain centralization during preparation and were associated with more significant apical transport compared to ProDesign M®.

Numerous techniques for root canal preparation and filling are described in the literature, each with specific indications, characteristics, advantages, and disadvantages. Given the inherent limitations in the physicochemical properties of endodontic obturation sealers, such as solubility, it is generally recognized that a higher proportion of gutta-percha about the amount of sealer used in obturation is associated with better long-term prognosis^{5,6}.

According to existing literature, oval canals account for approximately 25% of cases. These types of root canals are most commonly encountered in lower incisors and upper premolars with a single root canal, where the prevalence can reach as high as 50%. It may also be present in approximately 25% of the distal roots of lower molars⁷.

As a result, this study aims to evaluate the quality of obturation achieved using various methods in the context of oval root canal preparation conducted with M® instruments.

MATERIALS AND METHODS

This study was approved by the Research Commission of the Faculty of Dentistry and the Research Ethics Committee of the Federal University of Rio Grande do Sul (UFRGS) under the CAAE Process 53815421.0.0000.5347. All experimental procedures were carried

out by a single operator who had undergone prior training.

Sample selection

The study utilized a total of sixty oval-shaped root canals from lower premolars obtained in the dental surgery discipline at the UFRGS dental school. Patients provided informed consent for the study. Teeth with oval canals were included if the canal diameter in the buccolingual aspect was at least twice larger than the mesiodistal diameter at any level in the coronal thirds of the canal. Exclusion criteria were applied to root specimens displaying fracture lines or cracks, evidence of prior endodontic procedures, atretic or calcified pulp chambers, any signs of dental resorptions, and/or incomplete rhizogenesis.

Furthermore, the selected teeth were required to have a length ranging from 20 to 22 mm, as measured using a digital caliper (Digimatic Caliper - Mitutoyo), extending from the buccal cusp to the apex of the tooth.

Preparation and endodontic treatment of samples

The root canal preparation process was carried out as follows:

- Initially, the crowns of the teeth were removed at the cemento-enamel junction using a carborundum disc (KG Sorensen Ind. Com. Ltda., Barueri, São Paulo, Brazil) under continuous irrigation.
- The initial exploration of the canals was performed using a manual endodontic instrument made of stainless steel #15 type K

(Dentsply/Maillefer Instruments S.A., Ballaigues, Switzerland). The instrument was gradually advanced millimeter by millimeter until the tip was positioned at the foraminal exit, confirmed with the aid of a stereoscopic magnifying glass with 3.5 times magnification (Bio-Art Equipamentos Odontológicos Ltda., São Carlos, São Paulo, Brazil). A 1 mm treatment was performed from this point, establishing the working length (WL).

- After canal exploration, the #25/.06 M® manual instrument (Easy Equipamento Odontológicos, Belo Horizonte, Minas Gerais, Brazil) was used to perform pre-enlargement of the cervical and middle thirds of the root canal with continuous movements in the clockwise direction.

- The #25/.01 M® instrument was then used until the canal achieved patency with continuous clockwise movements.

- Once patency was confirmed with the #25/.01 instrument, the #15/.05, #25/.06, and #35/.05 M® instruments were used, all at the working length and with the same instrumentation kinematics as previously applied. The continuous movements in the clockwise direction were clockwise after penetration and engagement of the instrument inside the canal in an apical direction.

- Before using each instrument, the root canal was irrigated with a 2.5% sodium hypochlorite solution (Iodontosul - Industrial Odontológica do Sul LTDA, Porto Alegre, RS, Brazil). An irrigation volume of 10 mL was applied between each instrument used. The irrigating solution remained

Table 2. Mean percentage values (%) of unfilled spaces in the root segments of the different experimental groups.

Experimental Groups	Root third			P
	Cervical	Middle	Apical	
	% mean (\pm SD)	% mean (\pm SD)	% mean (\pm SD)	
TU	6.95 ^{Ba} (\pm 0.65)	31.07 ^{Cc} (\pm 2.37)	12.11 ^{Cb} (\pm 1.00)	<0.0001
TL	1.87 ^{Aa} (\pm 0.33)	1.55 ^{Aa} (\pm 0.35)	1.06 ^{Aa} (\pm 0.28)	>0.05
TH	9.19 ^{Cc} (\pm 0.89)	6.95 ^{Bb} (\pm 0.96)	3.12 ^{Ba} (\pm 0.66)	<0.0001
TS	1.02 ^{Aa} (\pm 0.45)	0.33 ^{Aa} (\pm 0.04)	0.29 ^{Aa} (\pm 0.05)	>0.05
P	<0.0001	<0.0001	<0.0001	

Means followed by different uppercase letters in the column and means followed by different lowercase letters in the row differ significantly through the Analysis of Variance, at a significance level of 5%.

within the root canal during the use of each instrument in the preparation.

- Following instrumentation, the canals were filled along their entire WL with 17% trisodium EDTA (Iodontec Indústria e Comércio de Produtos Odontológicos Ltda., Porto Alegre, Rio Grande do Sul, Brazil) and the solution was agitated using the E1 ultrasonic insert (Helse Dental Technology, São Paulo, São Paulo, Brazil). The insert was introduced to a standardized length of 3 mm beyond the working length and activated for 30 seconds with ultrasound (Jet-Sonic Four Plus, Gnatus, Ribeirão Preto, São Paulo, Brazil) without cooling, using power scale 2 for Endodontics. EDTA remained within the canal for 3 minutes.

- After this period, the canals were flushed with 10 mL distilled water (Iodontosul - Industrial Odontológica do Sul LTDA, Porto Alegre, Brazil) and dried using absorbent paper cones (Tanari Indústria Ltda., Manaus, Amazonas, Brazil).

Division of experimental groups

The teeth were randomly allocated to four experimental groups (**Table 1**) using a simple random sampling technique conducted within the Excel program (Microsoft Excel, Microsoft, USA).

Endodontic filling

For the endodontic filling procedure, the main gutta-percha cone from the M® system (Easy Equipamento Odontológicos, Belo

Horizonte, Minas Gerais, Brazil), B7 secondary gutta-percha cones (Tanariman Industrial Ltda., Amazonas, Brazil), and Bio-C Sealer bioceramic sealer (Angelus, Londrina, Paraná, Brazil) were employed.

In the TU group, a single cone obturation technique was employed. The primary cone coated with endodontic sealer was inserted into the WL.

The cold lateral compaction technique was applied to the teeth in the TL group. The endodontic sealer was introduced into the root canal with the primary cone. Subsequently, accessory gutta-percha cones were also inserted into the canal, coated with a sealer, within the spaces created by the bi-digital spacer B (Dentsply/Maillefer Instruments S.A., Ballaigues, Switzerland), extending as far as possible, aided by clinical tweezers. The obturation process concluded when no more cones could be introduced into the root canal.

For the TH group, Tagger's hybrid technique was employed. Initially, the primary cone was placed, followed by cold lateral compaction to secure three additional secondary gutta cones. After inserting the third secondary cone, the gutta-percha cones were compacted using a #50 McSpadden® condenser (Dentsply/Maillefer Instruments S.A., Ballaigues, Switzerland), positioned 4 mm short of the WL to ensure proper filling of the middle and cervical thirds of the canal⁸.

In the TS group, obturation was carried out using vertical condensation in Schilder's technique. The primary cone coated with endodontic sealer was inserted into the WL, and a compactor was heated using a heat source and introduced into the root canal, reaching up to 4 mm short of the WL. Upon removal, a portion of gutta-percha was displaced, and the condenser was re-inserted into the canal to perform condensation movements and vertical compaction in the softened gutta-percha at the most apical region. Small sections of non-standard gutta-percha were employed to fill the middle and cervical thirds of the canal. These sections were heated with the same heat source and compacted using larger-diameter compactors.

Following the filling procedure, all cones were trimmed at the cervical level of the root with the assistance of a Paiva condenser (Duflex®).

Analysis of filling the root canal

Following obturation, digital radiographs were captured using a digital sensor (Fona CDR, Schick, Petržalka, Slovakia) with the following parameters: 70 kV, 7 mA, and an exposure time of 0.1 seconds. Radiographs were taken from two orientations: buccolingual and mesiodistal.

Adobe Photoshop v. 10.0 (Adobe Systems, San Jose, CA, USA) was utilized to define and calculate the filled area and empty areas within each

Table 3. Mean percentage values (%) of unfilled spaces in the different experimental groups in both radiographic directions.

Experimental Groups	Radiographic directions		P
	buccolingual % mean (\pm SD)	mesiodistal % mean (\pm SD)	
TU	11.74 ^A (\pm 1.31)	21.68 ^B (\pm 2.26)	<0.0001
TL	1.08 ^A (\pm 0.20)	1.90 ^B (\pm 0.31)	<0.0001
TH	5.76 ^A (\pm 0.76)	7.08 ^A (\pm 0.79)	0.2336
TS	0.43 ^A (\pm 0.21)	0.66 ^A (\pm 0.22)	0.4597

Means followed by different capital letters in the line differ significantly using the t-test, at the 5% significance level.

of the root thirds and along the entire length of the filled canal.

Statistical analysis

Data normality was assessed using the Shapiro-Wilk test. For statistical analysis, the one-way ANOVA and Student's t-test were employed, followed by Tukey's multiple comparison test when necessary. The significance level was set at 5% ($P \leq 0.05$). Statistical analysis was conducted using the GraphPad Prism 7 program (GraphPad Software Inc., San Diego, CA, USA).

RESULTS

The average percentages of unfilled spaces in the various experimental groups within different canal regions are presented in **Table 2**. Irrespective of the analyzed root third, the TL and TS groups exhibited the lowest mean percentages of unfilled spaces, with statistical significance observed compared to the TU and TH groups. **Figure 1** visually represents the obturation patterns observed in the experimental groups. When comparing the root thirds within each experimental group, differences were noted solely in the TU and TH groups.

Table 3 illustrates that variations in the filling quality between the two radiographic perspectives were only significant in the TU and TL groups, with the highest average percentage of unfilled spaces

observed in the mesiodistal view.

DISCUSSION

The filling phase of the root canal system plays a pivotal role in the success of endodontic treatment. Its objective is to achieve a compact and three-dimensional filling of the void spaces previously occupied by pulp tissues, facilitating the tissue repair process⁹. Moreover, the prognosis of the treated tooth is contingent on the quality of the root filling¹⁰.

Numerous gutta-percha techniques have been advocated to attain a homogeneous filling material mass, with cold lateral compaction being one of the most commonly used^{9,11}. However, studies such as those by Peng et al.¹² (2007) used this technique with heterogeneous obturations, thus indicating an

excessive presence of filling sealer. To mitigate these issues, techniques were developed that thermoplastic gutta-percha, allowing it to adapt more effectively to the intricate root canal system as it becomes more pliable when heated¹³. One such technique, Tagger's hybrid technique, combines cold lateral compaction with thermomechanical compaction using a McSpadden instrument. Martins et al.⁹ (2011) compared these techniques with a third method. Although all three methods left residual spaces, lateral condensation yielded superior results, aligning with the present study's findings. The presence of failures in obturation with Tagger's hybrid technique may be related to the operator's method of using the compactor.

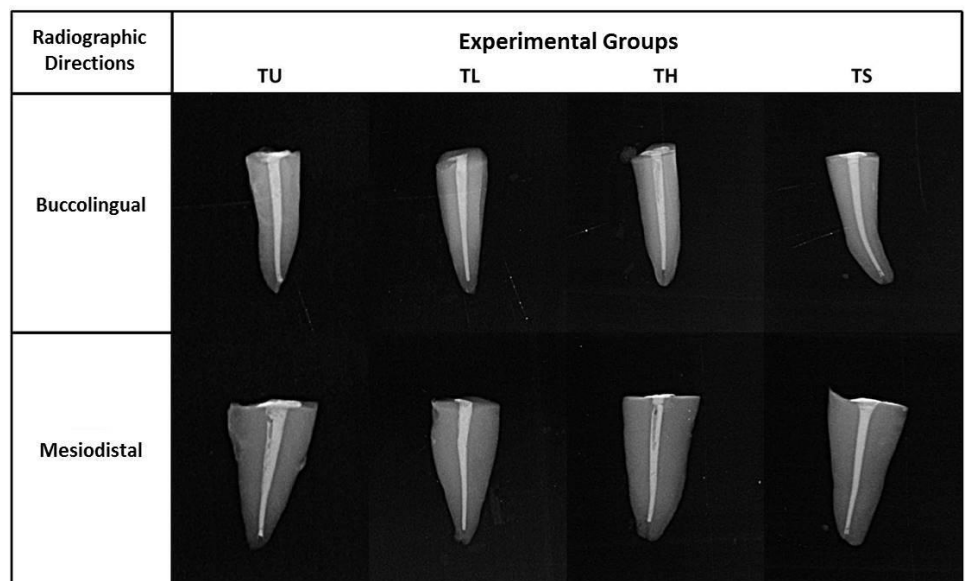


Figure 1. Illustrative image of the obturation pattern visualized by the radiographic directions in the different experimental groups.

The single cone technique for filling root canals was introduced concurrently using rotary instruments for root canal preparation¹⁴. In this technique, the gutta-percha cone employed for obturation possesses a shape similar to that of the instrument used for root canal preparation^{15,16}. Following mechanical and chemical preparation, the instrument-like caliber cone is inserted into the canal's working length alongside the chosen sealer material¹⁷. However, to enhance sealing quality and ensure better adaptation of the root canal filling, thermoplasticization techniques for gutta-percha should be considered^{17,18}. Dentists widely favor the single cone technique due to its ease of application and minimal time requirement¹⁹. However, as indicated by Kim et al.²⁰ (2018), this technique may not adequately fill the irregularities of the canal because the central cone carries a substantial amount of endodontic sealer. This observation aligns with the present study's findings, particularly when examining radiographs in the mesiodistal direction. Although mesiodistal radiographs are not routinely used in clinical practice, it is essential to acknowledge that even when the canal appears well-obtured and compacted on buccolingual radiographs, it may exhibit deficiencies when radiographed in the proximal direction.

Conversely, the vertical compaction technique, involving the application of heat to plasticize gutta-percha and sealer, aided by a condenser connected to a heat source, followed by apical condensation using a cold instrument²¹, proved to be highly effective in achieving satisfactory root canal filling in this study.

Further research involving alternative methods to assess filling depth would be beneficial to provide a more precise recommendation for the optimal

obturation technique in oval root canals.

CONCLUSION

The cold lateral compaction and Schilder's filling techniques were the ones that promoted better filling in oval root canals prepared with M@ instruments.

ACKNOWLEDGEMENTS

The authors deny any conflict of interest.

REFERENCES

- García-Guerrero C, Delgado-Rodríguez CE, Molano-González N, Pineda-Velandia GA, Marín-Zuluaga DJ, Leal-Fernandez MC, et al. Predicting the outcome of initial non-surgical endodontic procedures by periapical status and quality of root canal filling: a cohort study. *Odontology*. 2020;108(4):697-703.
- Patel S, Puri T, Mannocci F, Bakhsh AA. The outcome of endodontic treatment using an enhanced infection protocol in specialist practice. *Br Dent J*. 2022;232(11):805-811.
- Silva PLA, Neves GSM, Praxedes LFS, Castro FLA, Bruno KF. O impacto dos instrumentos endodônticos ProDesign M no ensino de graduação. *Dental Press Endod*. 2022;12(2):37-43.
- Zarpelon FI, Barp EM, Galafassi D, Melo TAF. Analysis of preparation time, wear, transportation and centering ability of Flexofile and Prodesign® M manual instruments in curved root canals preparation. *Rev Odonto Cienc*. 2018;33(1):58-63.
- Wu MK, Ozok AR, Wesselink PR. Sealer distribution in root canals obturated by three techniques. *Int Endod J*. 2000;33(4):340-5.
- Li GH, Niu LN, Zhang W, Olsen M, De-Deus G, Eid AA, et al. Ability of new obturation materials to improve the seal of the root canal system: a review. *Acta Biomater*. 2014;10(3):1050-1063.
- Wu MK, R'oris A, Barkis D, Wesselink PR. Prevalence and extent of long oval-shaped canals in the apical third. *Oral Surg Oral Med Oral Pathol Oral Radiol Endod*. 2000;89(6):739-743.
- Tagger M, Tamse A, Katz A, Korzen BH. Evaluation of the apical seal produced by a hybrid root canal filling method, combining lateral condensation and thermatic compaction. *J Endod*. 1984;10(7):299-303.
- Martins SC, Mello J, Martins CC, Maurício A, Ginjeira A. Comparação da obturação endodôntica pelas técnicas de condensação lateral, híbrida de Tagger e Thermafil: estudo piloto com Micro-tomografia computadorizada. *Revista Portuguesa de Estomatologia, Medicina Dentária e Cirurgia Maxilofacial*. 2011;52(2):59-69.
- Kirkevang L, Hørsted-Bindslev P. Technical aspects of treatment in relation to treatment outcome. *Endod Topics*. 2002;2:89-102.
- Cailleteau JG, Mullaney TP. Prevalence of teaching apical patency and various instrumentation techniques in united states dental school. *J Endod*. 1997;23(6):394-6.
- Peng L, Ye L, Tan H, Zhou X. Outcome of Root Canal Obturation by Warm Gutta-Percha versus Cold Lateral Condensation: A Meta-analysis. *J Endod*. 2007;33(2):106-109.
- De Deus G, Reis C, Beznos D, Abranches AMG, Coutinho-Filho T, Paciornik S. Limited Ability of Three Commonly Used Thermoplasticized Gutta-Percha Techniques in Filling Oval-shaped Canals. *J Endod*. 2008;34(11):1401-1405.
- Girelli CF, Lacerda MF, Lemos CA, Amaral MR, Lima CO, Silveira FF, et al. The thermoplastic techniques or single-cone technique on the quality of root canal filling with tricalcium silicate-based sealer: an integrative review. *J Clin Exp Dent*. 2022;14(7):e566-e572.
- Fruchi LC, Ordinola-Zapata R, Cavenago BC, Duarte MAH, Bueno CE,

Martin AS. Efficacy of reciprocating instruments for removing filling material in curved canals obturated with a singlecone technique: a micro-computed tomographic analysis. *J Endod.* 2014;40(7):1000-4.

16. Celikten B, Uzuntas CF, Orhan AI, Orhan K, Tufenkci P, Kursun S, et al. Evaluation of root canal sealer filling quality using a singlecone technique in oval shaped canals: an In vitro Micro-CT study. *Scanning.* 2016;38(2):133-40.

17. Kim S, Kim S, Park JW, Jung IY, Shin SJ. Comparison of the percentage of voids in the canal filling of a calcium silicate-based sealer and gutta percha cones using two obturation techniques. *Materials (Basel).* 2017;10(10):1-13.

18. Faus-Llácer V, Collado-Castellanos N, Alegre-Domingo T, DolzSolsona M, Faus-Matoses V. Measurement of the percentage of root filling in oval-shaped canals obturated with Thermafil Obturators and Beefill 2in1: In vitro study. *J Clin Exp Dent.* 2015;7(2):e299-303.

19. Cavenago BC, Duarte MAH, Zapata RO, Marciano MA, Perochena AEC, Bramante CM. Interfacial adaptation of an epoxy-resin sealer and a self-etch sealer to root canal dentin using the System B or the single cone technique. *Braz Dent J.* 2012;23(3):205-211.

20. Kim J, Hwang Y, Rosa V, Yu M, Lee K, Min K. Root Canal Filling Quality of a Premixed Calcium Silicate Endodontic Sealer Applied Using Gutta-percha Cone-mediated Ultrasonic Activation. *J Endod.* 2018;44(1):133-138.

21. De Deus G, Murad C, Paciornik S, Reis CM, Coutinho-Filho T. The effect of the canal-filled area on the bacterial leakage of oval-shaped canals. *Int Endod J.* 2008;41(3):183-190.