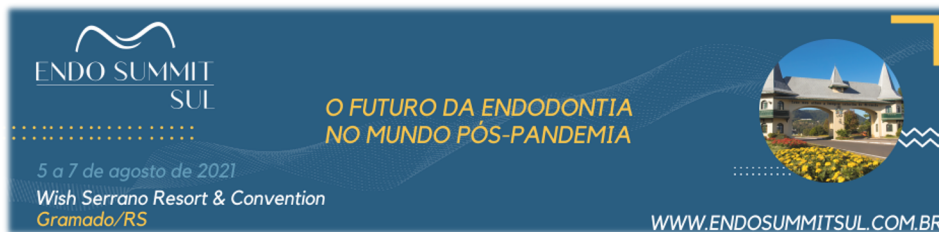




## ABSTRACTS 3<sup>RD</sup> ENDO SUMMIT SUL RESUMOS 3<sup>º</sup> ENDO SUMMIT SUL



### **178/1001-0**

#### **ENDODONTIC MANAGEMENT OF A FIRST LOWER PREMOLAR WITH 3 CANALS: A CASE REPORT**

##### **CLINICAL CASE**

**RAFAELA RICCI e BRUNA SIGNOR**

*UNIVERSIDADE DE PASSO FUNDO (UPF)*

This study aimed to report the endodontic management of a mandibular first premolar with three canals and independent foramina. In most cases, premolars present a single and broad root canal. However, mandibular first premolars may present variations in morphology and in number of root canals, which increases the endodontic treatment complexity. The tooth presented a trifurcation in the middle third and three distinct canals with independent foramina. Endodontic treatment was performed with the aid of an operating microscope. Cone beam computed tomography and operative microscope

were essential to establish the correct diagnosis given the mandibular premolar anatomic variation. Thus, the association of these two tools facilitated a proper endodontic management, increasing the chances of success.

Keywords: Premolar; Root Canal; Endodontics

### **178/1002-0**

#### **RADIOTHERAPY FOR HEAD AND NECK CANCER INDUCES PULP NECROSIS? SYSTEMATIC REVIEW WITH META-ANALYSIS**

##### **LITERATURE REVIEW**

**THEODORO WEISSHEIMER, BRUNA BARCELOS SÓ, MARIELI CHITOLINA PRADEBON, JOSÉ ANTÔNIO POLI DE FIGUEIREDO, MANOELA DOMINGUES MARTINS, MARCUS VINICIUS REIS SÓ e MARCUS VINICIUS REIS SÓ.**

*UNIVERSIDADE FEDERAL DO RIO GRANDE DO SUL.*

The aim of this review was to answer the question whether radiotherapy in patients with head and neck cancer can induce pulp necrosis. Searches were performed based on the PICOS strategy in the following databases: PubMed, Cochrane Library, EMBASE, Web of Science, Scopus and Open Grey. Only clinical studies that assessed the pulp status of patients with head and neck cancer undergoing radiotherapy were selected. Risk of bias was assessed using the ROBINS-I tool. Meta-analyses were performed using fixed effects models. The quality of evidence was assessed with the GRADE tool. Of 171 studies identified in the initial searches, 68 were removed as they were duplicates. After titles and abstracts reading, 5 studies were included for final analysis. Pulp status was verified by cold thermal testing (CTT), electrical testing (ET) and pulse oximetry (PO). In general, treatments consisted of isolated radiotherapy using intensity-modulated radiotherapy (IMRT), with total doses between 60-70Gy.

Significant changes for CTT responses were observed in post-radiotherapy periods ( $n = 4$ ;  $I^2 = 0\%$ ; 95% CI;  $P < 0.00001$  /  $n = 3$ ;  $I^2 = 0\%$ ; 95% CI;  $P < 0.00001$ ), being mostly negative responses. Significant changes in ET were seen in post-radiotherapy periods ( $n = 2$ ;  $I^2 = 68\%$ ; 95% CI;  $P < 0.00001$ ), with a significant increase in the electrical dose for response. PO revealed a significant reduction in pulpal blood flow with the consequent return to normal values, however, meta-analyses were not possible. Three studies had a serious risk of bias, and two a moderate risk. GRADE analysis showed a moderate quality of evidence. Radiotherapy in patients with head and neck cancer does not induce pulp necrosis. CTT and ET should not be used as conclusive diagnostic methods of necrosis.

**Keywords:** Pulp necrosis; Dental pulp; Radiotherapy

#### **178/1004-0**

### **CLINICAL VISUALIZATION OF ENTEROCOCCUS FAECALIS ENDOODONTIC BIOFILM THROUGH FLUORESCENCE USING TWO FLUOROPHORS**

#### **SCIENTIFIC RESEARCH**

**LÍVIA RAMOS ALVARIZA, MARIELI PRADEBON, THAIS MARCHAND e JOSÉ ANTONIO POLI DE FIGUEIREDO**

UNIVERSIDADE FEDERAL DO RIO GRANDE DO SUL

Some bacteria, such as *Enterococcus faecalis*, are more resistant to endodontic procedures, being able to survive in the root canal system. Bacteria remaining inside the root canals, can lead to persistent infections, unsuccessful treatments or even tooth extraction. There is a great difficulty in clinically identifying the biofilm and bacteria within the root canal system. Thus, fluorescence rises as a new method to reduce the problem of clinical visualization of the

endodontic infection. This study evaluated, by means of fluorescence and the use of fluorophores, the presence of *Enterococcus faecalis* inside the root canals. Eighteen bovine teeth, with a single canal, were selected. Teeth were decoronate, close to the cemento-enamel junction, with a length equal to 16mm. Longitudinal grooves were made on the buccal and palatal surfaces of the samples and cleaning and preparation was performed with ultrasound. Root canals were infected with *Enterococcus faecalis* and incubated for 29 days for biofilm development, with renewal of the culture medium every 48 hours. After this period, teeth were divided into 3 groups: negative control, calcein group and qubit protein group. Teeth were clinically visualized using the ReVeal system, consisting in a 2.5x magnifying glass with an Ultraviolet photophore, allowing the observation of the fluorophores effectiveness in canals infected with *Enterococcus faecalis*. It was observed that both fluorophores were effective in the presence of bacteria. Negative control group did not fluoresce. Calcein had greater luminosity but showed light scattering. Qubit protein had a uniform luminescence, without image scattering.

**Keywords:** *Enterococcus faecalis*; Fluorescence; Biofilm

Study approved by the UFRGS [Research Ethics Committee](#) (34070)

#### **178/1005-0**

### **INTERNAL MORPHOLOGY OF THE LOWER INCISIVE ROOT CANAL BASED ON TWO CLASSIFICATIONS: MICROTOMOGRAPHY STUDY**

#### **SCIENTIFIC RESEARCH**

**FERNANDA FRIEDRICH, FABIANA VIEIRA VIER-PELISSER, MURILO PRIORI ALCALDE, MARCO ANTÔNIO HÚNGARO DUARTE, RODRIGO RICCI**

**VIVAN, RICARDO ABREU DA ROSA E MARCUS VINÍCIUS REIS SÓ**

UNIVERSIDADE FEDERAL DO RIO GRANDE DO SUL

To investigate the root canal configurations of mandibular incisors (MI) using Vertucci (1984) and Ahmed et al. (2017) classification, accessed by micro computed tomography ( $\mu$ CT). A total of one hundred and sixty-five human permanent MIs were scanned using a high-resolution  $\mu$ CT. Two examiners classified the samples based on the coding systems of Vertucci and Ahmed et al. The Kappa coefficient was used to assess the degree of agreement between examiners. The most significant proportion of MIs had a single root canal along the entire root (52.1%). Type III (1-2-1) Vertucci and 1 MI 1-2-1 Ahmed et al. were the most common type of root canal in 2-canals incisors (20%). In the apical third, the presence of one, two and three canals were found in 81.8%, 15.2% and 3% of the samples, respectively. In the cervical and middle thirds, 1, 2 and 3 root canals were found in 86%, 12.2% and 1.8%, respectively. Ahmed et al. classification managed to classify the entire studied sample, and 11 teeth (6.66%) did not fit the Vertucci classification. Ahmed et al. classification describes root and canal configurations in a more complete and practical way compared to Vertucci classification and should be encouraged in  $\mu$ CT internal dental anatomy studies.

**Keywords:** Dental anatomy; Endodontic; Micro-computed tomography

[Ethics committee approval:](#) 03668018.1.0000.5347

#### **178/1006-0**

### **EVALUATION OF THE RADICULAR INTRADENTINAL PENETRABILITY OF A BIOCERAMIC SEALER AFTER THREE FINAL IRRIGATION PROTOCOLS.**

## SCIENTIFIC RESEARCH

**ANGÉLICA FENSTERSEIFER LEMOS,  
MARIELI CHITOLINA PRADEBON e  
MARCUS VINÍCIUS REIS SÓ**

*UNIVERSIDADE FEDERAL DO RIO  
GRANDE DO SUL (UFRGS)*

This study evaluated the occurrence of radicular intradental penetration of a ready-to-use bioceramic sealer, with three chemical substances (sodium hypochlorite, saline solution and deionized water) as irrigants preceding a final irrigation with phosphate buffer solution. Thirty distobuccal roots of maxillary molars were selected and digitally radiographed. Canals were instrumented with the reciprocating system X1 Blue #25.06 and #40.06 (MK Life, Porto Alegre, Brazil). Specimens were randomly allocated into three groups according to the irrigation protocol associated with passive ultrasonic activation (PUA): G-NaOCl (2.5% sodium hypochlorite + PUA), G-SS (0.9% saline solution irrigation + PUA) and G-H2O (irrigation with deionized water + PUA). All specimens were subjected to a phosphate buffer solution irrigation. Canals were filled with a single-cone technique and bioceramic sealer (Sealer Plus BC – MK Life) mixed with a specific fluorophore for calcium compounds. The roots were transversally sectioned and each root third was prepared for Confocal Laser Scanning Microscopy (CLSM). Images obtained in CLSM were analyzed for sealer penetration in the dentinal tubules. Regardless of the final irrigation protocol tested in this study, it was not possible to observe the penetration of the bioceramic sealer in the dentinal tubules in any root third of the studied groups. It is inferred that the intradental penetration of this bioceramic sealer may be related to multifactorial conditions that may interfere in the material properties.

Keywords: Endodontics; Calcium silicate-based sealer; Dentin tubule penetration  
Ethics committee approval: CAAE No. 23173219.0.0000.5347; decision 3,717,007

### **178/1008-0**

#### **EVALUATION OF CYCLIC FATIGUE, TORSIONAL RESISTANCE AND ANGLE DEFLECTION OF A NEW ENDODONTIC INSTRUMENT**

## SCIENTIFIC RESEARCH

**CHARLES ANDRÉ DALL AGNOL JÚNIOR, GIOVANA SIOCHETA DA SILVA, GABRIEL BARCELOS SÓ, MURILO PRIORI ALCALDE, RODRIGO RICCI VIVAN, MARCO ANTÔNIO HÚNGARO DUARTE, MARCUS VINÍCIUS REIS SÓ e RICARDO ABREU DA ROSA**

*UNIVERSIDADE FEDERAL DO RIO  
GRANDE DO SUL*

The aim of this study was to evaluate the cyclic fatigue and torsional resistance, and angular deflection of a new nickel-titanium (NiTi) instrument. Sixty instruments were selected: ProDesign Logic2 25.03 (n=20) and 25.05 (n=20) (Easy Equipamentos Odontológico, Belo Horizonte, Brazil) and Flat File 25.04 (n=20) (MK Life, Porto Alegre, Brazil). For the cyclic fatigue test, instruments were introduced into an artificial stainless-steel canal with a 60° angle and 5mm curvature radius located 5mm from the instruments tip. Cyclic fatigue test was performed at controlled room temperature (37.0 ± 1.0°C). Time to fracture was recorded and calculated. Torque and angle of rotation at failure were measured according to ISO 3630-1, in which the 3mm tip of each instrument was fixed and connected to a motor, a processor and a load cell. Torque (N/cm) to instrument fracture was measured and angular deflection at failure was recorded (in degrees). Statistical

analysis was performed using one-way ANOVA and Tukey post hoc tests. Flat File 25.04 instruments had a lower cyclic fatigue resistance than Logic 25.03 and 25.05 instruments (P < 0.05). Flat File 25.04 and Logic2 25.05 presented similar torque to fracture (P < 0.05) and both were more torque resistant than Logic2 25.03 (P < 0.05). Angular deflection was different for all tested instruments (P < 0.05), as follows: Logic2 25.03, Logic2 25.05 and Flat File 25.04. Mechanical properties of the evaluated instruments depended on their geometric features and thermal treatment of the NiTi alloy.

Keywords: Endodontics; Mechanical tests; Nickel-titanium instruments

### **178/1009-0**

#### **INTERNAL SUBSTITUTIVE PERFORATING RESORPTION: 10 YEARS OF PROSERVATION**

## CLINICAL CASE

**WESLEY MISAEL KRABBE, RICARDO ABREU DA ROSA and MÁRCIA HELENA WAGNER**

*FEDERAL UNIVERSITY OF RIO GRANDE  
DO SUL*

This study aimed to report a 10-year follow-up case of an internal substitutive perforating root resorption. A 19-years old female patient presented a considerable widening of the root canal on the periapical radiographic examination of the tooth 11. Cone beam computed tomography (CBCT) was ordered and revealed a hypodense area with irregular margins involving the entire space of the pulp cavity communicating with the periodontium. Due to the lesion characteristics, the diagnosis was of an internal substitutive perforating root resorption. Intraoral examination revealed a small pink spot on the cervical third of the buccal face. Tooth positively responded to the cold sensitivity test. There was a negative

response to apical palpation and percussion. Coronary access and partial pulp removal were performed with 1% sodium hypochlorite (NaOCl). Due to an intense bleeding, chemomechanical preparation was not completed. Calcium hydroxide paste was used as an intracanal medication. In the next appointment, chemomechanical preparation, removal of the metaplastic and granulation tissue from the reabsorbed area, and placement of the calcium hydroxide paste, that remained for 2 months, were performed. The canal was filled with mineral trioxide aggregate and the tooth restored with glass ionomer and composite resin. After obturation, a new CBCT was performed, showing the complete filling of the root canal and resorption defect. In the 10-year follow-up tomography, the root canal was filled with the filling material, including the communication area with the periodontium, demonstrating the success of the treatment due to the stagnation of the resorption process. The use of a restorative cement for root canal filling presenting internal substitutive perforating root resorption is an alternative for these cases. Clinical, radiographic, and tomographic follow-up are essential to assess the treatments' success.

**Keywords:** Endodontics; Root Resorption; Calcium Hydroxide

**178/1010-0**

**INFLUENCE OF PHARMACOLOGICAL MANAGEMENT OF ANXIETY ON PAIN DURING ENDODONTIC TREATMENT: A SYSTEMATIC REVIEW**

**LITERATURE REVIEW**

**ISADORA AMES SILVA, CHARLES ANDRÉ DALL AGNOL JÚNIOR, THEODORO WEISSHEIMER, MARCUS VINICIUS REIS SÓ and RICARDO ABREU DA ROSA**

**FEDERAL UNIVERSITY OF RIO GRANDE DO SUL – UFRGS**

The negative connotation of endodontic procedures can increase the patient's anxiety and, consequently, the occurrence of pain. The aim of this systematic review was to answer the question: Does the pharmacological management of anxiety influence the occurrence of pain during root canal treatment? Electronic databases (MEDLINE/PubMed, Cochrane Library, Web of Science, Scopus, EMBASE and Open Gray) were searched until February 2021. Only randomized controlled trials (RCTs) were included. The Cochrane risk of bias tool for randomized clinical trials (RoB 2) was used to assess the included studies. The overall quality of evidence was assessed using the Grading of Recommendations Assessment, Development, and Evaluation (GRADE) tool. Initial screening of the databases resulted in 510 studies, of which 43 were excluded because they were duplicates. Of the 457 eligible articles, ten studies met the inclusion criteria and were selected for full text reading. Six studies were excluded for not having evaluated pharmacological interventions. Four studies were included, and an additional study was retrieved from its references. One RCT was classified as presenting an uncertain risk of bias, three as low risk of bias, and one as high risk of bias. GRADE analysis demonstrated a low quality of evidence. It is possible to conclude that benzodiazepines do not influence on pain occurrence during endodontic procedures. However, nitrous oxide gas decreased the occurrence of intraoperative pain.

**Keywords:** Endodontics; Anxiety; Pain

**178/1011-0**

**DOES THE APICAL LIMIT OF MECHANICAL PREPARATION MODIFY THE FORAMEN AND ROOT CANAL MORPHOLOGY?**

**SCIENTIFIC RESEARCH**

**MARIA EDUARDA PAZ DOTTO, TAMER FERREIRA SCHMIDT, DAYANA MARA SILVA CHAVES, JULIA MENEZES SAVARIS, CLEONICE DA SILVEIRA TEIXEIRA, LUCAS DA FONSECA ROBERTI GARCIA, THAIS MAGESTE DUQUE and EDUARDO ANTUNES BORTOLUZZI**

**FEDERAL UNIVERSITY OF SANTA CATARINA**

The aim of this study was to evaluate the influence of the mechanical preparation performed at three different working lengths (WL), through rotary and reciprocating kinematics, on the morphology of the apical foramen and root canal. Before and after preparation, 30 mesial roots of mandibular molars with 2 separate canals were scanned by computed microtomography and the apical foramina of the canals were photographed by stereomicroscope. Three groups were formed (n = 20) according to the WL: G-1 - foramen-1mm; G0 - foramen; and G+1 - foramen+1mm. Each group was divided into 2 subgroups (n = 10): G-1: Buchanan patency and manual foraminal debridement; G0 and G+1: rotary (Prodesign S #25/.08) and reciprocating (R25) foraminal enlargement. The area, perimeter, deviation and non-instrumented cemental wall (NICW) of the foramen were evaluated. Canal transportation and prepare centralization at 1, 3 and 5 mm from the foramen were evaluated. The ANOVA test was used for repeated measures to compare data on foraminal area and perimeter before and after preparation, and the Bonferroni test was used to identify the differences. For other variables, Kruskal-Wallis and Dunn tests were used. For all tests, a significance level of 5% was established. Regarding NICW, there were no differences between mechanized foraminal enlargements, which were similar to manual

foraminal debridement. There was no difference in canal transport and centralization at 1, 3 and 5 mm from the foramen, regardless of the kinematics. Preparations performed in the foramen or 1 mm beyond with Prodesign S #25/.08 and R25 files promoted foraminal enlargements, deviations and were not able to instrument the entire cemental wall. The instruments used were able to maintain the apical anatomy of the canal.

**Keywords:** Apical preparation limit; Foraminal enlargement; Apical patency

**Ethics committee approval:** 3,253,628

### **178/1012-0**

#### **INTERMEDIARY IRRIGATION FOR PREVENTION OF THE PRECIPITATE FORMED FROM THE INTERACTION OF IRRIGANT SOLUTIONS**

##### **SCIENTIFIC RESEARCH**

**MARIA EDUARDA PAZ DOTTO, EMANUELLE CATHERINE MAIOLA, LETÍCIA MENDES BOPPRÉ, JULIA MENEZES SAVARIS, DAYANA MARA SILVA CHAVES, LUCAS DA FONSECA ROBERTI GARCIA, CLEONICE DA SILVEIRA TEIXEIRA, THAIS MAGESTE DUQUE, LUIZ CARLOS DE LIMA DIAS JUNIOR and EDUARDO ANTUNES BORTOLUZZI**

FEDERAL UNIVERSITY OF SANTA CATARINA

The aim of this study was to evaluate the influence of distilled water (H<sub>2</sub>O) in preventing the brown-orange precipitate observed after the interaction between sodium hypochlorite (NaOCl) 2.5% and chlorhexidine (CHX) 2%. Fifty canines were instrumented, longitudinally divided, and analyzed under a stereomicroscope at 16x and 40x magnifications. Then, all teeth were reassembled and distributed into 5 groups according to the final irrigation protocol: G1 (control) – 17% EDTA +

NaOCl + CHX, with syringe; G2- 17% EDTA + NaOCl + CHX, with syringe + PUI (30s); G3 - 17% EDTA + NaOCl + H<sub>2</sub>O + CHX, with syringe and, with the exception of H<sub>2</sub>O, activated for 30s with PUI; G4 - 17% EDTA + NaOCl + H<sub>2</sub>O + CHX, with syringe + PUI (30s); G5 - 17% EDTA + NaOCl + H<sub>2</sub>O + CHX, H<sub>2</sub>O in CUI protocol, and applied with syringe + PUI (30s). The specimens were again analyzed under stereomicroscope. Final images after irrigation were classified by scores (0, 1, 2, 3) according to the amount of precipitate found. The statistical tests were performed with Kruskal-Wallis and Friedman tests ( $\alpha=5\%$ ). In all thirds, G1 had significantly higher scores than the other groups. There was no statistical difference between the experimental groups ( $p>0.05$ ). There was no difference between the thirds in the experimental groups ( $p>0.05$ ). Distilled water was effective in preventing precipitate formation when applied with a syringe, PUI and CUI.

**Keywords:** Chlorhexidine; Sodium hypochlorite; Irrigation

**Ethics committee approval:** 3,413,317

### **178/1013-0**

#### **HIGH-INTENSITY DIODE LASER IN ENDODONTIC PRACTICE - CLINICAL CASE REPORT**

##### **CLINICAL CASE**

**NATHALIA DA SILVA BARUFFI, DAIANE PERUZZO, CÁTIA CILENE NASS SEBRÃO and JÚLIO CÉSAR JOLY**

SÃO LEOPOLDO MANDIC

Knowledge of root anatomy demonstrates that standard shaping procedures, intracanal medication and irrigation are not sufficient for total bacterial elimination. This study aims to demonstrate a clinical case in which chemomechanical preparation was performed, associating the usage of a high-intensity diode laser, in an attempt to regress a lesion associated

to a primary infection. A 15-years old patient had an endodontic treatment initiated after demonstrating a radiolucent lesion between teeth 11 and 12. Patient did not reported pain and had a history of trauma in the anterior teeth. Percussion and vitality tests were performed, both presenting negative results. Both teeth were accessed and prepared as suggested by the standard protocols but, before the application of intracanal medication, a high-intensity laser was applied, in spiral movements to provide contact with all intraradicular walls, in a pre-established protocol of time and energy. After finishing the treatment, radiographs were taken, as well as clinical examination, after two and four months. It was observed that the use of laser as an adjunct to the endodontic treatment allowed a considerable regression of the lesion. Despite the success obtained in this case, the performance of studies is necessary to define a protocol for the application of laser.

**Keywords:** Lasers; Endodontics; Injuries and lesions

### **178/1014-0**

#### **ROOT CANAL AND DENTINAL TUBULES DISINFECTION THROUGH THE USE OF ENTEROCOCCUS FAECALIS BACTERIOPHAGES**

##### **SCIENTIFIC RESEARCH**

**MARIELI CHITOLINA PRADEBON, LIVIA RAMOS ALVARIZA, THAÍS MARCHAND, ANGÉLICA FENSTERSEIFER LEMOS, THEODORO WEISSHEIMER, ALEKSANDRA PALATINSKA-ULATOWSKA, LIVIU STEIER and JOSÉ ANTÔNIO POLI DE FIGUEIREDO**

FEDERAL UNIVERSITY OF RIO GRANDE DO SUL

Enterococcus faecalis is a facultative bacterium present in infected canals, that causes infections that are difficult to treat. It is a

predominant pathogen in persistent periapical infections and have the ability to form biofilms as one of its main characteristics. In addition, *E. faecalis* has increased virulence factors, greater adherence capacity and antimicrobial resistance. Bacteriophages or phages are a set of viruses capable of destroying specific disease-causing bacteria, by invading bacterial cells, interrupting their metabolism, and causing cell lysis. Prior to the discovery and use of antibiotics, phage therapy was an alternative to infections. For these reasons, this pilot study aimed to determine the potential use of bacteriophages in combating endodontic infections associated with *E. faecalis* as an aid to root canal and dentinal tubule disinfection. As this is a pilot study, a small sample size was used for its development. Nine single-rooted human teeth, contaminated with *E. faecalis*, were kept in Brain Heart Infusion (BHI) medium for bacterial culture for 29 days with changes every 48hrs. Teeth divided into three groups: negative control, positive control and experimental group. After culture, the samples were vertically sectioned, followed by visualization of the biofilm by means of bioluminescence, and the bacteriophages action by means of scanning electron microscopy (SEM). The results proved the bacteriophages and bioluminescence effectiveness against *E. faecalis*, being possible to notice a significant reduction of bacteria inside the root canal and dentinal tubules. This study allowed to outline an alternative treatment against endodontic biofilm, in addition to the action of antimicrobials, seeking to better understand the functioning of the endodontic biofilm, phages and their applications in Endodontics.

**Keywords:** Bacteriophages; Biofilm; *Enterococcus faecalis*

**178/1015-0**

**CLINICAL AND TOMOGRAPHIC FOLLOW-UP OF AN EXTERNAL ROOT RESORPTION IN A MAXILLARY CANINE: CASE REPORT**  
**CLINICAL CASE**

**LETÍCIA TAINÁ DE OLIVEIRA LEMES, BRUNA REMOR, SÍLVIA BALZAN, TIAGO LANGE DOS SANTOS and RENATA DEBONA CRESPI**

**FASURGS**

External root resorption is a pathological process, in which there is cementum, dentin and bone tissue degradation, that can occur in teeth with endodontically treated or vital teeth. External root resorption occurs by several factors, such as trauma, impacted third molars, excessive forces, occlusion, orthodontic treatment, and chemical irritation. Root resorption can occur in the cervical, middle, and apical thirds. External cervical resorption frequently occurs after or during orthodontic treatments, especially in maxillary canines. External cervical resorption (ECR) is characterized by a slow and asymptomatic process. The purpose of this clinical case report is to present the follow-up of a maxillary canine (23) with external root resorption. In this follow-up, imaging exams from 2016 and 2020 are presented, and it was possible to observe that the resorption process was stabilized and presenting signs of repair. Clinical examination, detailed anamnesis and periapical radiographs are fundamental to determine the pathology. Treatment planning is different for each case, depending on clinical and radiographic factors, causes and moment of resorption discovery, whether the structure of the remaining tooth is restorable and whether there is pulp involvement. In some case, by removing the pathogenic agent, resorption can be stopped, and mineralized tissue can be formed.

**Keywords:** Resorption; Endodontic treatment; Orthodontic treatment

**178/1016-0**  
**SINUSITIS OF ENDODONTIC ORIGIN - CASE REPORT**  
**CLINICAL CASE**

**VINÍCIUS VIDAL CARVALHO, ISABELLA STEDILE DOS SANTOS and MILENA PERRARO MARTINS**

**AVANTIS UNIVERSITY CENTER**

An Endodontic infectious inflammatory condition can affect the tissues and mucosa of the maxillary sinus adjacent to the root apex, causing an odontogenic sinusitis. The signs and symptoms that define the condition of an endodontic origin is called endo-antral syndrome, characterized by: an endodontic infection in a tooth close to the maxillary sinus, a periapical radiolucent image related to the affected tooth, loss of the lamina dura around the apex corresponding to the radiographic border of the maxillary sinus, radiopaque image in the maxillary sinus over the apex of the involved tooth and variation of radiopacity degrees in the image of the maxillary sinus affected by the inflammatory process, compared to the maxillary sinus on the opposite side. 40-years old patient, female, reported absence of taste and smells after COVID, tinnitus, severe pain in the right side of her face and temporomandibular disorder (TMD). After CBCT, it was observed that teeth 16 and 17 presented a communication between their roots and the maxillary sinus. Retreatment was performed in teeth 16 and 17 with ultrasonic inserts and Reciproc Blue files (VDW-Germany). Three changes of Ultracal XS dressing were performed until the symptom remission. Teeth were filled with BioRoot RCS sealer and gutta percha cones. After filling, a new CBCT was performed and, 3 months after the retreatments' beginning, bone repair was already observed. Patient reported no more pain, but still presenting tinnitus. We conclude that

as long as properly diagnosed, it is possible to treat odontogenic sinusitis through endodontic treatments. The use of CBCT becomes a potential tool for the diagnosis of this condition.

**Keywords:** Maxillary Sinusitis; Endodontics; Disclaimer.

**178/1017-0**

**ANALYSIS OF THE INFECTIOUS/ENDOTOXIC CONTENT OF ROOT CANALS FROM TEETH WITH SYMPTOMATIC AND ASYMPTOMATIC ENDODONTIC INFECTIONS**

**SCIENTIFIC RESEARCH**

**EZEQUIEL GABRIELLI, AUGUSTO RODRIGUES LIMA, PRISCILA AMANDA FRANCISCO, DANIEL RODRIGO HERRERA and BRENDA PAULA FIGUEIREDO DE ALMEIDA GOMES**

*FACULTY OF DENTISTRY OF PIRACICABA, STATE UNIVERSITY OF CAMPINAS (UNICAMP)*

This study aimed to investigate the presence of specific microorganisms in root canals and evaluate the levels of lipopolysaccharide (LPS) and lipoteichoic acid (LTA) in cases of symptomatic necrotic teeth with associated acute apical abscess (AAA – GI) and in asymptomatic necrotic teeth (GII) during endodontic treatment (ET) stages. Microbiological, LPS and LTA samples were collected in different phases of the ET: before chemomechanical preparation (CMP), after CMP, and after intracanal medication (IM), from 20 root canals and from AAA. The effectiveness of decontamination was evaluated by microbial culture. Nested-PCR was performed to investigate specific species of microorganisms. LPS levels were measured by the Limulus Amebocyte Lysate test. ELISA was used to quantify LTA. Data were analyzed by different statistical tests. LPS levels were higher in GI than in GII ( $p < 0.05$ ).

In GII, there was a significant reduction in LTA after CMP ( $p < 0.05$ ), whereas in GI the reduction was significant only after IM ( $p < 0.05$ ). In GI, there was an LPS reduction after CMP ( $p < 0.05$ ), whereas in GII the reduction was only significant after IM ( $p < 0.05$ ). *Enterococcus faecalis* and *Fusobacterium nucleatum* were frequently detected. LPS levels were higher in symptomatic cases and associated with spontaneous pain. It was concluded that different species can be detected at all stages of the ET. CMP can reduce the microbial load, however not LTA, whose levels remain high even after IM.

**Keywords:** Microorganisms;

Lipopolysaccharide; Lipoteichoic acid.

**Ethics committee approval:**

86.140.218.0.0000.5418

**Financial Support:** FAPESP (processes 2017/18459-0; 2015/23479-5), CAPES (001) & CNPq (303852/2019-4)

**178/1018-0**

**GENOTOXICITY AND CYTOTOXICITY OF THREE ENDODONTIC SEALERS ON HUMAN PERIODONTAL LIGAMENT STEM CELLS**

**SCIENTIFIC RESEARCH**

**BÁRBARA LUZIA CAPITANIO, BRUNA BARCELOS SÓ, MANOELA DOMINGUES MARTINS, THEODORO WEISSHEIMER, MÁRCIA MARTINS MARQUES, MARIA STELLA MOREIRA and MARCUS VINICIUS REIS SÓ**

*FEDERAL UNIVERSITY OF RIO GRANDE DO SUL (UFRGS)*

Currently, there are few studies on genotoxicity of bioceramic endodontic sealers. This study aimed to evaluate the genotoxicity and cytotoxicity of Sealer Plus BC, AH Plus and MTA Fillapex. Human periodontal ligament stem cells (hPDLSCs) were cultured in a 96-well culture plates and characterized by flow cytometry and stem cell surface markers. The tested

groups were fresh culture medium (control), Sealer Plus BC, AH Plus and MTA Fillapex. Genotoxicity was evaluated by means of micronucleus formation and cytotoxicity by MTT assay. Cytotoxicity assessment was performed in accordance with ISO 10993-5. Statistical analysis for genotoxicity was performed using Kruskal-Wallis and Dunn tests and two-way ANOVA for cytotoxicity. The cells expressed typical levels of mesenchymal stem cell surface markers. There were no differences in the number of micronuclei among all groups. In all analyzed periods (24 hours, 48 hours, and 72 hours), the sealers presented statistically different results for cell viability, with Sealer Plus BC presenting the lowest cytotoxicity, followed by the control group, MTA Fillapex and, finally, AH Plus. In conclusion, all sealers had low genotoxicity and Sealer Plus BC had the lowest cytotoxicity.

**Keywords:** genotoxicity, cytotoxicity, endodontic cements

**Ethics committee approval:**

40392214.5.0000.0075

**178/1019-0**

**INFLUENCE OF THE OBTURATION TECHNIQUE ON THE QUALITY OF OBTURATIONS ASSESSED BY MICRO-CT: A SYSTEMATIC REVIEW**

**SCIENTIFIC RESEARCH**

**GABRIEL BARCELOS SÓ, NATÁLIA BACKA ABRAHÃO, THEODORO WEISSHEIMER, RICARDO ABREU DA ROSA, MARCUS VINÍCIUS REIS SÓ e RICARDO ABREU DA ROSA**

*FEDERAL UNIVERSITY OF RIO GRANDE DO SUL (UFRGS)*

This systematic review aimed to investigate the influence of the obturation technique on the quality of obturations assessed by computed microtomography (micro-CT). A bibliographic search was performed in six electronic databases (PubMed,

Cochrane, Scopus, Web of Science, EMBASE and Open Gray). The search strategy combined the following terms: "Root canal filling"; "Root canal obturation"; "Obturation technique"; "Root canal filling technique"; "Filling quality"; "Gaps"; "Voids"; "Empty spaces"; "MicroCT"; "Micro-CT"; "Microcomputed tomography. Eligibility criteria based on the PICOS strategy were P - extracted human permanent teeth, I - root canal filling using different techniques. C - lateral condensation technique, O - obturation quality (presence of bubbles and gaps) and S - in vitro studies. The risk of bias (RoB) of the included studies was assessed using an adaptation based on previous systematic reviews. The initial search resulted in 491 studies. 195 studies were excluded because they were duplicates. Of 281 eligible studies, 15 met the inclusion criteria and were selected for full reading. Of these, all were included for analysis. Seven studies had a high risk of bias, seven a moderate, and one had a low risk of bias. None of the obturation techniques were free of bubbles or gaps. Eight studies reported more gaps and bubbles when using the lateral condensation technique when compared to other techniques. One study reported that the lateral condensation had fewer gaps and bubbles when compared to other techniques. Six studies showed no difference in presence among techniques. This systematic review showed that no obturation technique performed on extracted teeth and evaluated by micro-CT is free of bubbles or gaps.

This systematic review was registered in the PROSPERO database (CRD42021235037).

**Keywords:** Root canal filling; Micro-CT; Systematic review

### **178/1021-0**

#### **INFLUENCE OF OBTURATION TECHNIQUES COMPARED TO THE LATERAL CONDENSATION**

#### **TECHNIQUE ON THE SUCCESS OF ENDODONTIC TREATMENTS: SYSTEMATIC REVIEW**

#### **SCIENTIFIC RESEARCH**

**LEONARDO THOMASI JAHNKE, DANIEL FEIJOLO MARCONI, GIOVANA SIOCHETA DA SILVA, THEODORO WEISSHEIMER, MARCUS VINÍCIUS REIS SÓ and RICARDO ABREU DA ROSA**

*FEDERAL UNIVERSITY OF RIO GRANDE DO SUL*

The aim of this systematic review was to answer the question: "What is the influence of different obturator techniques compared to the lateral condensation technique on the success rate of non-surgical endodontic treatment?". Electronic databases (MEDLINE/PubMed, Cochrane Library, Web of Science, Scopus, EMBASE and Open Gray) were searched until March 2021. Randomized clinical trials (RCT), non-randomized clinical trials (ECNR) and longitudinal studies were included. The Cochrane tools for risk of bias analysis of randomized clinical trials (RoB2) and non-randomized intervention studies (ROBINS-I) were used. The quality of evidence was assessed using the Grading of Recommendations, Assessment, Development and Evaluations (GRADE) tool. Of 458 studies, 255 were excluded because they were duplicates. Another 183 studies were excluded after title and abstract reading. Eleven studies were included for analysis. Different techniques were analyzed (vertical compaction, single cone, thermoplasticized, gutta-percha carriers). Clinical and radiographic parameters were used to determine success. In most studies there was no difference in the success rate of endodontic treatments performed by lateral condensation technique compared to other techniques. Higher success rates were associated with the

vertical compaction technique in two studies and lower rates in one study that used the single cone technique. Follow-up times varied between 2 months and 6 years. Two RCTs had a low risk of bias, and two a moderate risk of bias. For the nRCTs and longitudinal studies, a moderate risk of bias was observed in five studies, and a critical risk in two studies. The quality of evidence was classified as very low to moderate. Based on the available evidence, there are no differences in the clinical and radiographic success rates of different obturation techniques compared to the lateral condensation technique.

### **178/1022-0**

#### **INFLUENCE OF DIFFERENT ENDODONTIC SEALERS ON FIBERGLASS POST ADHESION**

#### **SCIENTIFIC RESEARCH**

**RAFAEL NESELLO, ISADORA AMES SLVA, IGOR ABREU DE-BEM, KAROLINA BISCHOFF, MATHEUS ALBINO SOUZA, MARCUS VINICIUS REIS SÓ and RICARDO ABREU DA ROSA**

*FEDERAL UNIVERSITY OF RIO GRANDE DO SUL*

The aim of this study was to evaluate the influence of different endodontic sealers on fiberglass posts adhesion, using conventional and self-adhesive resin cements. Sixty single-rooted human teeth were selected. Canals were prepared with X1Blue 40.06 (MK Life). Roots were randomly distributed in six groups (n=10) as follows: G1) AH Plus/RelyX ARC; G2) AH Plus/RelyX U200; G3) BioC Sealer/RelyX ARC; G4) BioC Sealer/RelyX U200; G5) Sealer Plus BC/RelyX ARC; G6) Sealer Plus BC/RelyX U200. The roots were perpendicularly sectioned and three slices per root were obtained, each corresponding to a post third (cervical, middle and apical). Push-out test was



performed. To analyze the failure pattern, specimens were analyzed under an optical microscope at 10× magnification. Bond strength was calculated and analyzed using ANOVA and Tukey tests with a significance level of 5%. The bond strength values of posts cemented with conventional resin cement (RelyX ARC) or with self-adhesive resin cement (RelyX U200) previously filled with AH Plus were similar ( $P > 0.05$ ). The lowest bond strength values were observed for the groups in which bioceramic sealers and conventional resin cement were associated (Bio C Sealer/RelyX ARC and Sealer Plus BC/RelyX ARC) ( $P < 0.05$ ). Adhesive failures between cement and post, and between cement and dentin were predominant (55.3%). Bioceramic sealers negatively influenced the bond strength values of fiber posts cemented with conventional resin cement.

**Keywords:** Root canal filling; Endodontic cement; Fiber post  
**Ethics committee approval:** 3.999,155

**178/1023-0**

**GENERAL PRACTITIONERS PERFORMANCE FACING COMPLEX AND CHALLENGING CASES IN ENDODONTICS.**

**CLINICAL CASE**

**LUAN NOGUEIRA LUCAS and MILENA PERRARO MARTINS**

**CEMO INSTITUTE**

Endodontic treatments performed by general practitioners is very common in large clinics and dental offices routine. Often, due to limitations (scientific and technological) and to complex cases, there is the need for an expert opinion. On contrary, theoretical knowledge combined with technology allows the clinicians to solve complex cases without needing for patient's referral. This successful case report aims to show a challenging case performed by

a general practitioner with 2 years and 5 months training, presenting major complexities such as perforations, deviations, fractured instrument, pulp necrosis, and periapical lesion. Endodontic treatment was performed in 3 sessions, with the aid of operating microscope, ultrasound, digital radiographic sensor, and other technological devices that contributed to the case resolution. After completion, two follow-ups were performed (radiographic - 05/2021 - and tomographic - 07/2021), showing a significant lesion regression and repair.

**178/1024-0**

**USE OF ENDOGUIDE IN A CALCIFIED MANDIBULAR CANINE: CASE REPORT**

**CLINICAL CASE**

**AUDREY MACHADO, and MILENA PERRARO**

In cases where the treatment of calcified canal must be done, calm and patience are required, as the endodontic access in these situations can, inadvertently, facilitate the occurrence of accidents that can cause great loss of dental structure or perforations. Endoguide can be successfully used in these cases, when a more accurate access without excessive deviations is needed. This technique is also recommended for less experienced clinicians. 30-years old male patient, presented with an extreme calcification of the pulp chamber and root canal on tooth 43. Tomographic exams and scanning of the mandibula were requested so that the guiding device could be planned. An appointment was scheduled to verify the guide's adaptation. After that, a new attempt was made with Endoguide to locate the root canal. Even with the use of Endoguide, it was not possible to locate the root canal. This unsuccessful attempt was due to

some distortion occurred during the tomographic exams or mandibula scanning. A new Endoguide was made, through new scanning and tomography. Even with Endoguide, the endodontist expertise was essential for the clinical case success. Endoguide can fail due to procedural errors in tomography and scanning execution, providing images that are not able to be correctly reconstructed in the planning software.

**178/1025-0**

**RELATION BETWEEN THREE INSTRUMENTATION LEVELS AND THE FILLING OF THE ROOT CANAL APICAL THIRD**

**SCIENTIFIC RESEARCH**

**DAYANA MARA SILVA CHAVES, MORGANE MARION KUNTZE, MATHEUS POMPEO CALDAS SILVEIRA, TAMER FERREIRA SCHMIDT, CLEONICE DA SILVEIRA TEIXEIRA, JULIA MENEZES SAVARIS, MARIA EDUARDA PAZ DOTTO, LUCAS DA FONSECA BDUORTI GARCIA and EDUARDO ANTUNES BORTOLUZZI**

**FEDERAL UNIVERSITY OF SANTA CATARINA**

This study evaluated the relation between three levels of instrumentation and the quality of the filling of the root canal apical third. Sixty root canals were prepared using instruments in continuous rotation or reciprocating motion, distributed into three groups according to a pre-established working length (WL): G-1 (WL=CD-1); G0 (WL=CD); G+1 (WL=CD+1). Each group was subdivided (n=10) into two groups, according to foraminal intervention: G-1BP: Buchanan patency and G-1MF: manual file; G0Rot: rotary; and G0Rec: reciprocating preparation; G+1Rot: rotary; and G+1Rec: reciprocating preparation. Groups G-1BP, G-1MF, G0Rec and G+1Rec were prepared up to the WL with an R25 file and groups

G0Rot and G+1Rot with a Prodesign S file. Obturation level for all groups was established at CD-1. Images at 1, 2, and 3mm and at the foramen were obtained to assess the foramen and the apical third filling and whether there was overfilling. Data analyzes was performed using Pearson's Chi-Square ( $P = 0.05$ ). There was no association between the preparation and gutta-percha cone level ( $p > 0.05$ ). Sealer's leakage was greater in G0 and G+1 than in G-1. In G0 and G+1, 63% and 65% of the specimens had the entire apical foramen filled, while in G-1: 17.6%. In the 1mm section, 100% of the specimens were filled in G0 and G+1, whereas in G-1: 64.7% ( $p < 0.05$ ). There was no association between kinematics and obturation quality ( $p > 0.05$ ). It was concluded that there was no association between preparation levels and overfilling; the preparation levels in CD and CD+1 had a higher occurrence of endodontic sealer extrusion and filling of the foramen and apical third; kinematics did not influence the foramen and apical third filling.

**Keywords:** Apical level; Root canal preparation; Filling; Single cone.

**Ethics committee approval:** 3,253,628

### **178/1026-0**

#### **EFFECT OF IRRIGATION PROTOCOLS ON THE DENTIN AND ON THE FILLING MATERIAL BOND-STRENGTH**

##### **SCIENTIFIC RESEARCH**

**JULIA MENEZES SAVARIS, MARIA EDUARDA PAZ DOTTO, DAYANA MARA SILVA CHAVES, LUCAS DA FONSECA ROBERTI GARCIA, CLEONICE DA SILVEIRA TEIXEIRA and EDUARDO ANTUNES BORTOLUZZI**

FEDERAL UNIVERSITY OF SANTA CATARINA - UFSC

The aim of this study was to compare the effect of different final irrigation protocols on the dentinal

structure and filling material bond-strength (BS) to dentin. One hundred and eight teeth were instrumented and distributed into four groups, according to the final irrigation protocol: CG (control) - EDTA + passive ultrasonic irrigation (PUI); G1 - 3 PUI cycles (20s each): NaOCl + EDTA + NaOCl; G2 - EDTA (PUI 30s) + NaOCl (PUI 30s); G3 - EDTA + NaOCl + H<sub>2</sub>O + CHX (PUI 30s each). After protocols, each group were submitted to three tests: three-point flexural strength ( $n=48$ ), microhardness (Knoop) ( $n=12$ ) and filling material BS dentin (push-out) ( $n=48$ ). Dentinal erosion was assessed using scores assigned to Scanning Electron Microscopy images. Data normality was verified by Shapiro-Wilk. Data were statistically analyzed (ANOVA and Tukey - flexural strength and push-out resistance; Student's t test - microhardness; Kruskal-Wallis and Friedman - erosion, with  $\alpha=5\%$ ). For flexural strength, there was no statistical difference among groups. For microhardness, a difference was detected, except in the GC group. In the push-out, the middle and apical thirds of G2 presented higher values ( $p < 0.05$ ). CG showed significantly lower erosion scores than G1, G2 and G3, and G1 was higher than G3 ( $p < 0.05$ ). There were no differences between root thirds. It was concluded that different protocols caused dentinal erosion and changed its microhardness, but did not affect its flexural strength. The combined protocol of EDTA + NaOCl, for 30s each, presented the best results regarding the filling material bond-strength to dentin.

**Keywords:** Passive Ultrasonic Irrigation; Dentin; Irrigation Solutions  
**Ethics committee approval:** 3,413,317

### **178/1027-0**

#### **POST-OPERATIVE PAIN INCREASE AFTER ADDITIONAL ENLARGEMENT OF ROOT CANAL PREPARATION - RANDOMIZED CLINICAL TRIAL**

##### **SCIENTIFIC RESEARCH**

**FABIO DE ALMEIDA GOMES, ALINE DE LIMA HÄRTER, EDUARDA CARRERA MALHAO, SAMANTHA RODRIGUES XAVIER and FERNANDA GERALDO PAPPEN**

FEDERAL UNIVERSITY OF PELOTAS

The fact that single-file preparation is incapable in resulting completely disinfect root canals, makes room for the idea that further enlargement of the endodontic preparation would be necessary to optimize root canal disinfection, especially in cases of pulp necrosis. The aim of this study was to evaluate the influence of additional root canal enlargement of single-file preparation on the incidence and intensity of postoperative pain after endodontic treatment of 46 mandibular molars with pulp necrosis and radiographically visible periapical lesion (PAI Index). A prospective, randomized, double-blind, single-center clinical trial was developed. Groups were randomly divided into: Group 1: instrumentation completed using a single reciprocating file (Reciproc System, VDW); Group 2: instrumentation was performed with additional enlargement after single file preparation, using an instrument immediately larger than the previous one. Postoperative pain and analgesic intake were assessed after 24h, 48h and 7 days using a numerical scale (NRS). Intergroup comparison was performed using Mann-Whitney U tests. The incidence of postoperative pain and frequency of analgesic intake were analyzed with the chi-square test with statistical significance of  $P < 0.05$ . After 24h, the incidence of postoperative pain was significantly higher in group 2 ( $P = 0.033$ ), but similar in the periods of 48h ( $P = 0.135$ ) and 7 days ( $P = 1.000$ ). Mean postoperative pain levels were significantly higher after 24h in group 2 ( $P = 0.015$ ), however, with no

difference after 48h ( $P = 0.068$ ) and 7 days ( $P = 0.317$ ). It is concluded that further enlargement of the root canal preparation in mandibular molars with pulp necrosis and periapical lesion resulted in higher incidence and intensity of postoperative pain after 24hs of the endodontic treatment, without impact after 48h and 7 days.