



## SUCCESSFUL REVASCULARIZATION PROCEDURE IN AN IMMATURE PERMANENT NECROTIC SECOND LOWER MOLAR: A CASE REPORT WITH 4.5-YEARS FOLLOW-UP

Luana Heck<sup>1</sup>, Theodoro Weissheimer<sup>1</sup>, Marco Antonio Hungaro Duarte<sup>2</sup>, Rodrigo Ricci Vivan<sup>2</sup>, Murilo Priori Alcalde<sup>3</sup>, Ricardo Abreu da Rosa<sup>1</sup>, Marcus Vinicius Reis S6<sup>1</sup>

1. Department of Endodontics, School of Dentistry, Rio Grande do Sul Federal University (UFRGS), Porto Alegre, RS, Brazil;

2. Department of Operative Dentistry, Endodontics and Dental Materials, Bauru School of Dentistry, University of São Paulo (USP), São Paulo, SP, Brazil;

3. Health Science Center, Sacred Heart University, Bauru, São Paulo, SP, Brazil

CORRESPONDING AUTHOR: theodoro.theo@hotmail.com

### ABSTRACT

**Background:** Infection control is mandatory for revascularization procedures, enabling to eliminate patient's clinical symptoms and signs. Despite presenting a complex morphology when compared to anterior teeth, if a strict disinfection protocol is adopted and the revascularization procedure's biological principles are followed, the therapy can be successful in molar teeth.

**Methods:** This case report aims to present a clinical case of successful revascularization in an immature permanent necrotic second lower molar. Clinical decisions and explanations regarding possible mechanisms related to the treatment's success in a tooth with complex morphology are discussed.

**Results:** Revascularization procedures were performed on a 12-year-old male patient diagnosed with symptomatic periapical periodontitis in a tooth 37. The case highlights the need for infection control and biological principles that surrounds the success of this therapy. Follow-up times presented in this case were six months, 1, 2, 4 and 4.5-years, respectively. Continued root development was observed, and the tooth remains intact and without symptoms.

**Conclusion:** The association of infection control and the biological principles of revascularization procedures allow the maintenance and continuation of tooth development, even when these present complex morphologies.

**Keywords:** Apexogenesis; Infection Control; Molar; Revascularization.

<http://dx.doi.org/10.19177/jrd.v9e3202112-18>

### INTRODUCTION

Revascularization in Endodontics is described as a biological procedure that follows tissue engineering principles, based on

the presence of stem cells, a scaffold, and growth factors.<sup>1,2</sup> Although initially introduced as an endodontic regenerative procedure, it is well established from histological studies that the structures formed are mainly

fibrous connective tissue and cementum- or bone-like tissue, instead of pulp-complex tissues.<sup>3-5</sup>

Manly performed in immature permanent teeth with necrotic pulp, this procedure aims to promote the

continued development of the root length and thickness.<sup>6</sup> These aspects could increase the teeth fracture resistance due to the deposition of mineralized tissue in the root canal when compared to the root canal filling with gutta-percha and endodontic sealer, apexification, and the use of apical barriers.<sup>6-10</sup>

Moreover, it is also well reported that revascularization procedures have a high long-term success rate<sup>6,11</sup> and, for these reasons, it should be presented as the first treatment option for immature permanent teeth presenting pulp necrosis,<sup>12</sup> since if a failure occurs, this procedure does not preclude other treatment alternatives.

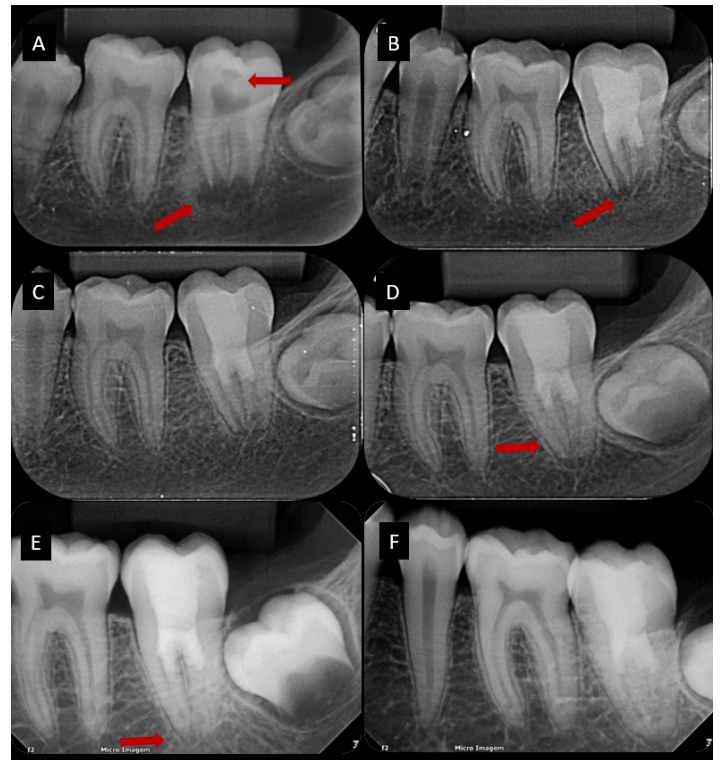
So far, there are several case reports of revascularization procedures, with a long-term follow-up, on anterior teeth and premolars.<sup>10,13-16</sup> However, only a few studies have evaluated the long-term outcome of such procedures in molars.<sup>17</sup> Although case reports do not provide enough evidence to support a treatment modality, it provides significant insights for clinical practice and can provide essential parameters for future research.<sup>18</sup> Therefore, this study reports a case of revascularization in an immature permanent necrotic second lower molar with 4.5-year of clinical and radiographic follow-up.

## CASE REPORT

A 12-year-old male patient was referred to a private endodontic office at Santa Cruz do Sul, Rio Grande do Sul, Brazil, in August 2016, reporting spontaneous and continuous pain, located on the posterior region of the mandibular left side, without relief when using analgesic medication.

No history of comorbidities or dental trauma were reported by the patient or his caregivers. No alterations were verified during extraoral examinations. During intraoral examinations, it was verified the left

**Figure 1.** A) Initial periapical radiograph evidencing a carious lesion contacting the pulp chamber and a radiolucent image associated with an incomplete root development; B) 6-month follow-up periapical radiograph revealing absence of infection; C) 1-year follow-up periapical radiograph; D) 2-years follow-up periapical radiograph showing a significant thickening of the root walls; E-F) 4-years follow-up evidencing complete root formation and absence of infection.



mandibular second molar (tooth 37) partially erupted and presenting coronal caries and gingival tissue partially covering the tooth crown. Tooth 37 had positive responses to percussion and palpation and negative responses to the pulp sensibility test with cold spray and mobility. Also, there was no presence of a sinus tract.

A digital periapical radiograph (FIT - Digital Radiograph Sensor, Micro Imagem; Indaiatuba, SP, Brazil) with a radiographic positioner was performed (Fig. 1). It was verified the carious lesion contacting the pulp chamber and a radiolucent periapical image associated with incomplete root development. The tooth was diagnosed with symptomatic apical periodontitis. After discussing with the patient and his caregivers, revascularization was selected as the treatment option, and informed consent was obtained.

## Treatment procedures

### First visit

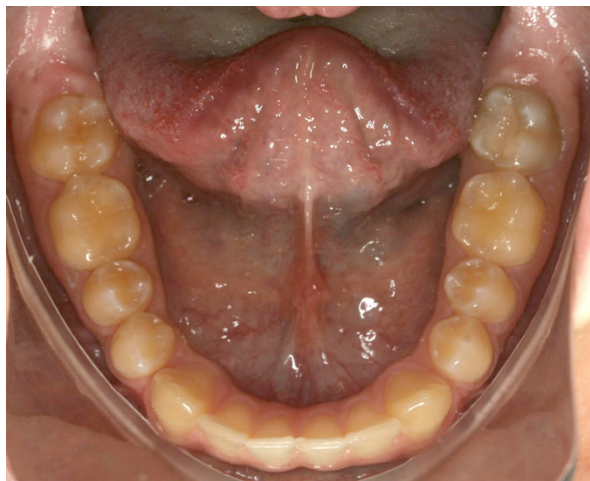
Inferior alveolar nerve block was performed using a 27-gauge needle (Injex - Industrias Cirúrgicas Ltda, Ourinhos, SP, Brazil) containing

1.8 mL of 2% lidocaine with 1: 100.000 epinephrine (Alphacaine - Nova DFL Indústria e Comércio S/A, Curicica, RJ, Brazil). Plaque from the tooth surface was removed with prophylactic paste and rubber cups. Additional anesthesia was performed in the surrounding tissues, allowing the operator to cut the gingival tissue covering the crown with a sterile scalpel.

After that, the tooth was isolated with a rubber dam and metal clamp, and the crown/rubber dam interface was sealed with a light-curing gingival barrier (Top Dam - FGM, Joinville, SC, Brazil) to avoid any possible saliva contamination. The operative field was disinfected with 30% hydrogen peroxide (H<sub>2</sub>O<sub>2</sub>) for 30 seconds. Carious tissues were removed, and an access cavity was performed using a sterile high-speed diamond bur and Endo Z bur (KG Sorensen, São Paulo, SP, Brazil) under water-cooling. Completely necrotic pulp tissue was visualized, confirming the diagnosis.

Following the location of all canals (mesiobuccal, mesiolingual, and distal), 10 mL of 1% sodium

**Figure 2.** Clinical view of the patient's mandibular teeth after 4-year of the treatment, evidencing discoloration of tooth 37.



hypochlorite (NaOCl) were passively irrigated using a syringe with a 30-gauge NaviTip needle (Ultradent, South Jordan, UT, USA) in each canal. A periapical radiograph with a positioner and the same vertical angulation as the first (0°) was performed with a sterile #15 K-file (Dentsply Maillefer, Ballaigues, Switzerland) inserted in each canal to establish the working length. After establishing the working length - 16mm for all canals -, another 10 mL of 1% NaOCl were irrigated in each canal, and a sterile #80 K-file (Dentsply Maillefer) was inserted and gently brushed against the canal walls to disrupt the biofilm without removing dentinal tissue that could weaken the canal walls. Following biofilm disruption, 20 mL of sterile saline solution was irrigated in each canal to remove the chemical compounds.

The canals were aspirated with a microcannula (Capillary Tips, Ultradent, South Jordan, UT, USA) and a triple antibiotic paste (TAP - metronidazole 500mg + cefaclor 500mg + ciprofloxacin 500mg and 1 mL of the anesthetic solution as a vehicle) was inserted into the canals by using a Lentulo-spiral (Dentsply Maillefer, Ballaigues, Switzerland). A sterile cotton pellet was placed in the pulp chamber, and the tooth was temporarily restored with a glass-

ionomer cement (Ionoseal - VOCO, Cuxhaven, Germany).

#### Second visit

After 30 days, the patient returned for the continuation of the procedures. The inferior alveolar nerve block was performed using a 27-gauge needle (Injex) containing 1.8 mL of 3% mepivacaine without vasoconstrictor (Mepiv - Nova DFL Indústria e Comércio S/A, Curicica, RJ, Brazil), disinfection

and isolation were performed as previously described. The temporary restoration was removed with a sterile high-speed bur under water-cooling. The triple antibiotic paste was removed by irrigating 10 mL of 1% NaOCl in each canal. After removal, 10 mL of 17% ethylenediamine tetra acetic acid (EDTA - Farmácia Fórmula & Ação, São Paulo, SP, Brazil) was irrigated in each canal and retained for 5 min. Canals were aspirated with a microcannula (Ultradent), and a pre-bend sterile #40 K-file (Dentsply) was inserted 2 mm past the working length (18mm) and rotated to stimulate bleeding and the formation of a blood clot. When blood was verified filling the middle third of the root canal, a mineral trioxide aggregate (MTA - Angelus, Londrina, PR, Brazil) barrier was passively inserted and filled the canal entrances. The restoration was performed with glass-ionomer cement (Ionoseal) and Filtek Z350XT composite resin (3M ESPE, St Paul, MN, USA).

#### Follow-up

The tooth was evaluated regularly with clinical and radiographic examinations (Fig. 1). At 6-month follow-up, the patient reported no symptoms. Clinically, the pulp sensibility test with cold spray,

palpation, percussion, and mobility were negative. A periapical radiograph revealed an absence of infection but no root formation. At 1-year follow-up, the absence of symptoms was reported by the patient. Clinical parameters were negative, and a periapical radiograph revealed a thickening of the root walls, suggesting a continued root formation.

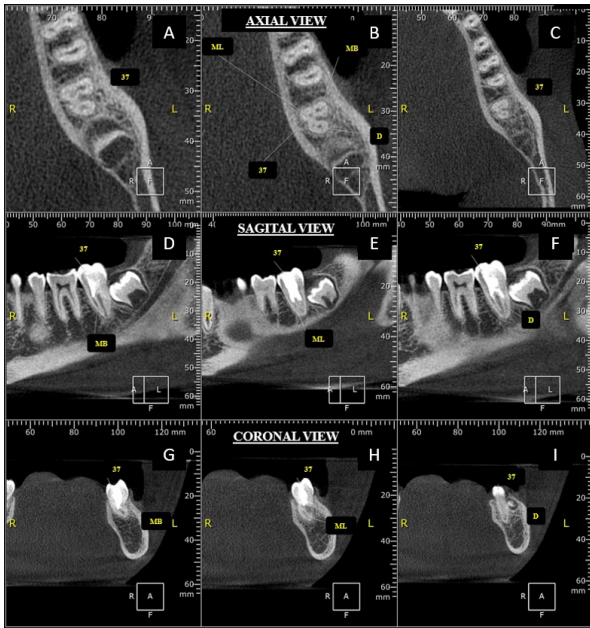
At 2-year follow-up, no symptoms were reported, and clinical parameters were all negative. Once again, a periapical radiograph was taken and revealed no signs of infection and significant thickening of the root walls. At 4-year follow-up, no symptoms were reported, clinical parameters were all negative, but a discoloration was observed in the tooth crown (Fig. 2). Radiographically, complete root development and absence of infection were observed.

At 4.5-year follow up, no symptoms were reported, clinical parameters were all negative and a cone-beam computed tomography (CBCT) scan was taken (Fig. 3). CBCT images were acquired using a Gendex GXCB-500 unit (Gendex/Kavo Dental, GmbH, Biberach, Germany), operating at 120kV, 5 mA, 0.2mm voxel size, field of view (FOV) of 776 x 776mm and exposure time of 6 seconds. Images were evaluated using OnDemand 3D software (Cybermed, Irvine, CA, USA) and adjusted to multiplanar views according to the long axis of each root. Image magnification, edge enhancement, brightness and contrast adjustments were used to allow a better evaluation of the images.

It was verified complete root development and bone healing, and normality of the periodontal ligament and lamina dura, confirming the success of the therapy.

## DISCUSSION

Revascularization procedures were first introduced by Nygaard Östby<sup>19</sup> and then improved by Iwaya et al.<sup>20</sup> and Banchs and Trope.<sup>7</sup> Since then,



**Figure 3.** Cone-beam computed tomography after 4.5-year of the treatment. **A-C)** Axial; **D-F)** sagittal; **G-I)** coronal views of the tooth, evidencing complete root development, absence of infection, and normality of the periodontal ligament and lamina dura.

a growing number of studies have been presenting high success rates related to these procedures.<sup>6,11,21</sup>

Although revascularization procedures follow principles of tissue engineering,<sup>2</sup> the presence of infection can present a significant challenge on the treatment outcome since neither tissue growth nor repair occurs in the presence of infection.<sup>22,23</sup> An infection could damage tissue-forming cells and stem cells in the periapical tissues.<sup>24</sup> Also, by promoting an inflammatory process, the infection can lead to the presence of pro-inflammatory cytokines, which may be able to inhibit the stem cells differentiation potential into tissue-committed somatic cells, jeopardizing the treatment outcome.<sup>25-27</sup>

The main challenge presented in this case was that the revascularization procedures were performed in a second mandibular molar. It is well reported the varied morphology presented by mandibular molars,<sup>28-31</sup> as well as the association between complex morphologies and bacterial maintenance on the treatment outcome.<sup>32</sup> Furthermore, few studies have shown endodontic regenerative procedures in molar teeth. A retrospective study reported

only one molar tooth treated with revascularization procedure and a follow-up of 61-months.<sup>17</sup>

In this case, a strict disinfection protocol was adopted. NaOCl was used in a lower concentration for being less cytotoxic<sup>33,34</sup> and for presenting a lower detrimental effect on dental pulp stem cells (DPSCs)<sup>34</sup> than at higher concentrations. Also, a large volume of NaOCl was used. Thus, even in lower concentrations, the biofilm removal and antimicrobial capacity of the NaOCl were not affected,<sup>35</sup> favoring disinfection.

Although the American Association of Endodontists Clinical Considerations for a Regenerative Procedures<sup>36</sup> does not recommend mechanical instrumentation, in the present case, a minimal debridement was performed with a large diameter manual file in order to disrupt biofilm attached to the dentinal walls. This procedure was performed because it has been reported that the leading cause of revascularization failure is due to the presence of remaining infection.<sup>22,37,38</sup> Also, a triple antibiotic paste was placed as intracanal dressing. In addition to presenting excellent disinfection effectiveness, the use of a combination of antibiotics may

decrease the risk of developing resistant bacterial strains due to the different mechanisms of action of the antibiotics.<sup>39,40</sup>

In addition to presenting a weak antimicrobial activity,<sup>41</sup> EDTA plays an essential role as a mediator of the cellular processes. Many biologically active growth factors trapped in the dentin matrix during the dentinogenesis, capable of promoting the survival, proliferation, and differentiation of DPSCs, are solubilized by EDTA, increasing their bioavailability.<sup>42,43</sup> Also, EDTA prevents the deleterious effects of NaOCl on stem cell survival and differentiation<sup>34</sup> and induces stem cell migration, attachment to the dentin surface, and odontoblastic/osteoblastic differentiation.<sup>44,45</sup>

In necrotic cases of immature teeth, it has been verified necrotic pulp tissue colonized by bacterial biofilm and alteration in the apical tissues, such as highly reduced cellularity or lack of cells in the apical papilla and discontinuation or absence of the Hertwig's epithelial root sheath (HERS).<sup>46</sup> It has been suggested that these alterations could compromise the completion of apexogenesis.<sup>46</sup> However, it has been suggested that the combination of the stronger immune defensive mechanism from young patients and the increased pulp blood circulation into the canal space due to the wide-open apex of immature teeth could effectively carry cellular and molecular components of innate and adaptive immune defense system into this space, which could improve the teeth resistance to carious infection.<sup>4,9,10</sup>

In this case, bleeding was induced, and MTA was used as a coronal barrier. Although it has been reported that the use of platelet-rich plasma (PRP) could provide results in a shorter time than the induced bleeding technique,<sup>47</sup> it requires drawing blood from the patient and

biochemical processing, which cause discomfort to the patient and increases the cost of the procedure. Since the follow-up period is still mandatory, regardless of the technique used, the induced bleeding technique seems to be a better treatment alternative since the techniques' success rates are similar.<sup>48</sup> Although the use of a collagen membrane is preconized, in this case, MTA was passively inserted in direct contact with blood. Since the use of a collagen membrane does not influence the treatment's success rate<sup>49</sup> but only assures the positioning of the sealing material, the use of this material was not preconized in this case. The choice for an MTA barrier is supported in the literature<sup>50</sup> due to the potential to induce mineralization and odontogenic/osteogenic differentiation on human papilla stem cells.

The crown discoloration is a recurrent problem in revascularization procedures and is often related to TAP containing minocycline<sup>51</sup> and MTA.<sup>52</sup> In this case, discoloration was only verified at a 4-year follow-up. Since minocycline was not used in the TAP composition, the discoloration was probably related to the MTA.<sup>53,54</sup> However, in this case, discoloration was not a patient's complaint, probably because it occurred in a mandibular posterior tooth, causing no esthetic loss.

The revascularization procedures' main advantages are the possibility to control infection and continue the root development, which could increase the fracture resistance of the tooth. Also, if failure occurs, there is still the possibility to perform a conventional root canal treatment.

## CONCLUSION

This study reported a successful case of revascularization on a second lower molar. Despite presenting greater morphological complexities than anterior teeth, this

should not be a factor that determines the impossibility of performing such procedures. The long-term follow-up presented in this case, associated with the clinical and radiographic success, validates the above statement.

## REFERENCES

1. Langer R, Vacanti JP. Tissue Engineering. Science. 1993;260(5110):920–26.
2. Murray PE, Garcia-Godoy F, Hargreaves KM. Regenerative endodontics: A review of current status and a call for action. *J Endod.* 2007;33(4):377–90.
3. Becerra P, Ricucci D, Loghin S, Gibbs JL, Lin LM. Histologic study of a human immature permanent premolar with chronic apical abscess after revascularization/revitalization. *J Endod.* 2014;40(1):133–39.
4. Shimizu E, Ricucci D, Albert J, Alobaid AS, Gibbs JL, Huang GTJ, et al. Clinical, radiographic, and histological observation of a human immature permanent tooth with chronic apical abscess after revitalization treatment. *J Endod.* 2013;39(8):1078–83.
5. Martin G, Ricucci D, Gibbs JL, Lin LM. Histological findings of revascularized/revitalized immature permanent molar with apical periodontitis using platelet-rich plasma. *J Endod.* 2013;39(1):138–44.
6. Jeeruphan T, Grad DDS, Sc C, High E, Dip G, Jantarat J, et al. Mahidol study 1 : Comparison of radiographic and survival outcomes of immature teeth treated with either regenerative endodontic or apexification methods. *J Endod.* 2012;38(10):1330–36.
7. Banchs F, Trope M. Revascularization of immature permanent teeth with apical periodontitis: New treatment protocol? *J Endod.* 2004;30(4):196–200.
8. Chueh LH, Huang GTJ. Immature teeth with periradicular periodontitis or abscess undergoing apexogenesis: A paradigm shift. *J Endod.* 2006;32(12):1205–13.
9. Kim SG, Malek M, Sigurdsson A, Lin LM, Kahler B. Regenerative endodontics: a comprehensive review. *Int Endod J.* 2018;51(12):1367–88.
10. Kim DS, Park HJ, Yeom JH, Seo JS, Ryu GJ, Park KH, et al. Long-term follow-ups of revascularized immature necrotic teeth: Three case reports. *Int J Oral Sci.* 2012;4(2):109–13.
11. Chrepa V, Joon R, Austah O, Diogenes A, Hargreaves KM, Ezeldeen M, et al. Clinical outcomes of immature teeth treated with regenerative endodontic procedures—A San Antonio study. *J Endod.* 2020;46(8):1074–84.
12. Diogenes A, Ruparel NB, Shiloah Y, Hargreaves KM. Regenerative endodontics: A way forward. *J Am Dent Assoc.* 2016;147(5):372–80.
13. Alsofi L. Regenerative endodontics for upper permanent central incisors after traumatic injury: Case report with a 3-year follow-up. *J Contemp Dent Pract.* 2019;20(8):974–77.
14. Arango-Gómez E, Nino-Barrera JL, Nino G, Jordan F, Sossa-Rojas H. Pulp revascularization with and without platelet-rich plasma in two anterior teeth with horizontal radicular fractures: a case report. *Restor Dent Endod.* 2019;44(4):1–10.
15. Maniglia-Ferreira C, Gurgel Filho ED, Gomes F de A, Reis SA, Pappen FG. 12-year follow-up of regenerative endodontic treatment of immature permanent upper incisors with acute abscess. *Braz Dent J.* 2020;31(6):680–84.
16. Suresh N, Arul B, Kowsky D, Natanasabapathy V. Successful regenerative endodontic procedure of a nonvital immature permanent central incisor using amniotic membrane as a novel scaffold. *Dent J.* 2018;6(3):1–8.

17. Silujjai J, Linsuwanont P. Treatment outcomes of apexification or revascularization in nonvital immature permanent teeth: A retrospective study. *J Endod.* 2017;43(2):238–45.
18. Jung IY, Lee SJ, Hargreaves KM. Biologically based treatment of immature permanent teeth with pulpal necrosis: A case series. *J Endod.* 2008;34(7):876–87.
19. Östby BN. The role of the blood clot in endodontic therapy. An experimental histologic study. *Acta Odontol Scand.* 1961;19:323–53.
20. Iwaya S, Ikawa M, Kubota M. Revascularization of an immature permanent tooth with periradicular abscess after luxation. *Dent Traumatol.* 2001;17(1):185–87.
21. Pereira AC, Oliveira ML, Cerqueira-Neto ACCL, Vargas-Neto J, Nagata JY, Gomes BPPA, et al. Outcomes of traumatised immature teeth treated with apexification or regenerative endodontic procedure: a retrospective study. *Aust Endod J.* 2021;47(2):178-87.
22. Lin LM, Shimizu E, Gibbs JL, Loghini S, Ricucci D. Histologic and histobacteriologic observations of failed revascularization/revitalization therapy: A case report. *J Endod.* 2014;40(2):291–95.
23. Myers WC, Fountain SB. Dental pulp regeneration aided by blood and blood substitutes after experimentally induced periapical infection. *Oral Surgery, Oral Med Oral Pathol.* 1974;37(3):441–50.
24. Kim S. Infection and Pulp Regeneration. *Dent J.* 2016;4(1):1–13.
25. Fouad AF, Nosrat A. Pulp regeneration in previously infected root canal space. *Endod Top.* 2013;28(1):24–37.
26. Liu C, Xiong H, Chen K, Huang Y, Yin X. Long-term exposure to pro-inflammatory cytokines inhibits the osteogenic/dentinogenic differentiation of stem cells from the apical papilla. *Int Endod J.* 2016;49(10):950–59.
27. Wang F, Jiang Y, Huang X, Liu Q, Zhang Y, Luo W, et al. Pro-inflammatory cytokine TNF- $\alpha$  attenuates BMP9-induced osteo/odontoblastic differentiation of the Stem Cells of Dental Apical Papilla (SCAPs). *Cell Physiol Biochem.* 2017;41(5):1725–35.
28. Abarca J, Abarca J, Duran M, Parra D, Steinfort K, Zaror C, et al. Root morphology of mandibular molars: A cone-beam computed tomography study. *Folia Morphol (Warsz).* 2020;79(2):327–32.
29. Ahmed HMA, Versiani MA, De-Deus G, Dummer PMH. A new system for classifying root and root canal morphology. *Int Endod J.* 2017;50(8):761–70.
30. Al-Qudah AA, Awawdeh LA. Root and canal morphology of mandibular first and second molar teeth in a Jordanian population. *Int Endod J.* 2009;42(9):775–84.
31. Amoroso-Silva PA, Ordinola-Zapata R, Duarte MAH, Gutmann JL, Del Carpio-Perochena A, Bramante CM, et al. Micro-computed tomographic analysis of mandibular second molars with c-shaped root canals. *J Endod.* 2015;41(6):890–95.
32. Siqueira Junior JF, Rôças I das N, Marceliano-Alves MF, Pérez AR, Ricucci D. Unprepared root canal surface areas: causes, clinical implications, and therapeutic strategies. *Braz Oral Res.* 2018;32(suppl 1):1–19.
33. Alkahtani A, Alkahtany SM, Anil S. An in vitro evaluation of the cytotoxicity of varying concentrations of sodium hypochlorite on human mesenchymal stem cells. *J Contemp Dent Pract.* 2014;15(4):473–81.
34. Martin DE, De Almeida JFA, Henry MA, Khaing ZZ, Schmidt CE, Teixeira FB, et al. Concentration-dependent effect of sodium hypochlorite on stem cells of apical papilla survival and differentiation. *J Endod.* 2014;40(1):51–5.
35. Carpio-perochena AE, Bramante CM, Duarte MAH, Cavenago BC, Villas-boas MH, Graeff MS, et al. Biofilm dissolution and cleaning ability of different irrigant solutions on intraorally infected dentin. *J Endod.* 2011;37(8):1134–38.
36. American Association of Endodontists Clinical Considerations for a Regenerative Procedure Revised 2018. <https://www.aae.org/specialty/wp-content/uploads/sites/2/2018/06/Clinical-Considerations-For-Reg-Endo-As-Of-April-2018.pdf>.
37. Chaniotis A. Treatment options for failing regenerative endodontic procedures: report of 3 cases. *J Endod.* 2017;43(9):1472–78.
38. Žižka R, Buchta T, Voborná I, Harvan L, Šedý J. Root maturation in teeth treated by unsuccessful revitalization: 2 case reports. *J Endod.* 2016;42(2):724–29.
39. do Couto AM, Espaladori MC, Leite APP, Martins CC, de Aguiar MCF, Abreu LG. A systematic review of pulp revascularization using a triple antibiotic paste. *Pediatr Dent.* 2019;41(5):341–53.
40. Mohammadi Z, Abbott P V. On the local applications of antibiotics and antibiotic-based agents in endodontics and dental traumatology. *Int Endod J.* 2009;42(7):555–67.
41. Busanello FH, Petridis X, So MVR, Dijkstra RJB, Sharma PK, van der Sluis LWM. Chemical biofilm removal capacity of endodontic irrigants as a function of biofilm structure: optical coherence tomography, confocal microscopy and viscoelasticity determination as integrated assessment tools. *Int Endod J.* 2019;52(4):461–74.
42. Bracks I V., Espaladori MC, Barros P, Brito LCN, Vieira LQ, Ribeiro Sobrinho AP. Effect of ethylenediaminetetraacetic acid irrigation on immune-inflammatory

response in teeth submitted to regenerative endodontic therapy. *Int Endod J*. 2019;52(10):1457–65.

43. Zeng Q, Nguyen S, Zhang H, Chebrolu HP, Alzebedeh D, Badi MA, et al. Release of growth factors into root canal by irrigations in regenerative endodontics. *J Endod*. 2016;42(12):1760–76.

44. Galler KM, Widbiller M, Buchalla W, Eidt A, Hiller KA, Hoffer PC, et al. EDTA conditioning of dentine promotes adhesion, migration and differentiation of dental pulp stem cells. *Int Endod J*. 2016;49(6):581–90.

45. Pang N-S, Lee SJ, Kim E, Shin DM, Cho SW, Park W, et al. Effect of EDTA on attachment and differentiation of dental pulp stem cells. *J Endod*. 2014;40(6):811–17.

46. Ricucci D, Siqueira JF, Loghin S, Lin LM. Pulp and apical tissue response to deep caries in immature teeth: A histologic and histobacteriologic study. *J Dent*. 2017;56:19–32.

47. Shivashankar VY, Johns DA, Maroli RK, Sekar M, Chandrasekaran R, Karthikeyan S, et al. Comparison of the effect of PRP, PRF and induced bleeding in the revascularization of teeth with necrotic pulp and open apex: A triple blind randomized clinical trial. *J Clin Diagnostic Res*. 2017;11(6):34–9.

48. Lolato A, Bucchi C, Taschieri S, Kabbaney A El, Fabbro M Del. Platelet concentrates for revitalization of immature necrotic teeth: a systematic review of the clinical studies. *Platelets*. 2016;27(5):383–92.

49. Jiang X, Liu H, Peng C. Clinical and radiographic assessment of the efficacy of a collagen membrane in regenerative endodontics: a randomized, controlled clinical trial. *J Endod*. 2017;43(9):1465–71.

50. Sanz JL, Forner L, Almudéver A, Guerrero-Gironés J, Llana C. Viability and stimulation of Human Stem Cells from the Apical Papilla (hSCAPs) induced by silicate-based

materials for their potential use in regenerative endodontics: A systematic review. *Materials (Basel)*. 2020;13(4):1-15.

51. Nagata JY, Soares AJ, Souza-Filho FJ, Zaia AA, Ferraz CCR, Almeida JFA, et al. Microbial evaluation of traumatized teeth treated with triple antibiotic paste or calcium hydroxide with 2% chlorhexidine gel in pulp revascularization. *J Endod*. 2014;40(6):778–83.

52. Torabinejad M, Nosrat A, Verma P, Udochukwu O. Regenerative endodontic treatment or mineral trioxide aggregate apical plug in teeth with necrotic pulps and open apices: A systematic review and meta-analysis. *J Endod*. 2017;43(11):1806–20.

53. Timmerman A, Parashos P. Bleaching of a discolored tooth with retrieval of remnants after successful regenerative endodontics. *J Endod*. 2018;44(1):93–7.

54. Tripathi R, Cohen S, Khanduri N. Coronal tooth discoloration after the use of white mineral trioxide aggregate. *Clin Cosmet Investig Dent*. 2020;12:409–14.