



# USE OF HEAT CURE CLEAR ACRYLIC AS A PERMANENT DENTURE BASE MATERIAL: A CASE REPORT

Sushma R.<sup>1</sup>, Anand Farias<sup>2</sup>, Tushar Shivaji Khandagale<sup>1</sup>, Pronob Kumar Sanyal<sup>1</sup>

<sup>1</sup> Department of Prosthodontics, Krishna Institute of Dental Sciences Deemed University, Karad, India  
<sup>2</sup> Department of Prosthodontics, Melaka Manipal Medical College, Manipal University, Melaka, India

CORRESPONDING AUTHOR: doc.sushma.r@gmail.com

## ABSTRACT

---

Clear acrylic denture base material finds its use in the fabrication of implant guides, surgical stents, and guiding flanges in dentistry. Given its excellent transparent property, the material will show the original gingival pigmentation which mimics the natural gingiva. In this case report one such attempt was made to use the clear acrylic denture so as to reflect the patients' original gingival pigmentation.

**KEYWORDS:** clear acrylic, gingiva, pigmentation

---

## INTRODUCTION

The life expectancy of the human population is increasing by the day due to the ever progressing health care systems and techniques. As a result we come across more number of geriatric patients in the dental office. These patients not only want us to replace their teeth but want us to restore their dental aesthetics to as near natural as possible. This poses a challenge in a literal sense and makes us think out of the box to make our patients feel better in terms of their dental function and aesthetics.

Aesthetics is "pertaining to the study of beauty and the sense of beautiful"<sup>1</sup>. Denture aesthetics is the effect produced by a denture that affects

beauty and attractiveness of a person<sup>2</sup>. Along with other aspects of denture fabrication, the denture base material plays a vital and important role in providing the aesthetics that the patient desires. The first acrylic resin was produced by Imperial Kolladent chemical dentistry in 1935. In 1937 heat-polymerized acrylics were developed by Walter H. Writer<sup>3</sup>. Since then, the heat cure acrylic has swept the conventional complete and/or partial denture arena. There have been many attempts to improve the physical properties of the denture base material to enhance its strength and aesthetics. The gingiva more than often is highly pigmented especially with Caucasians. Many a times

reproducing a heavily pigmented gingiva becomes impossible.

The present case report aims to present a case of a 65 old female patient with completely edentulous upper and lower arches with conventional complete dentures using the CLEAR heat cure acrylic denture base material to (show-off the natural colour of the gingiva which looks more aesthetic) reproduce the melanin pigmentation of the patients existing gingiva.

## CASE REPORT

A 65 year old female patient with completely edentulous upper and lower arches reported to the Department of Prosthodontics, School of Dental

Sciences, Karad, with a pair of dentures which she was not happy about. On examination it was found that the previously made dentures were non retentive, unstable and there was no occlusal harmony. Also the colour of the denture base material was a total miss match which was her main concern (Figures 1 to 3). Patient is otherwise healthy with no relevant medical history. Owing to her aesthetic concerns and the poor denture quality it was decided to fabricate a new prosthesis for the patient. Implant retained fixed prosthesis or implant supported removable prosthesis were given as options to the patient but she refused owing to the cost factor. Hence a decision was made to fabricate the new pair of complete dentures.

Figure 1. Old dentures in mouth.

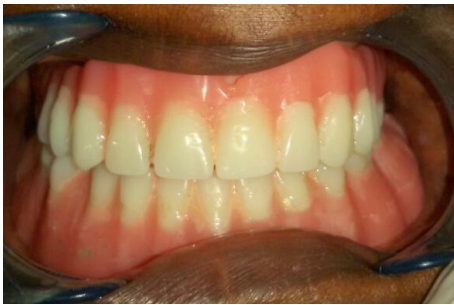
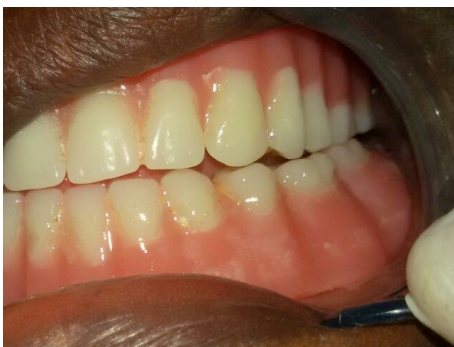
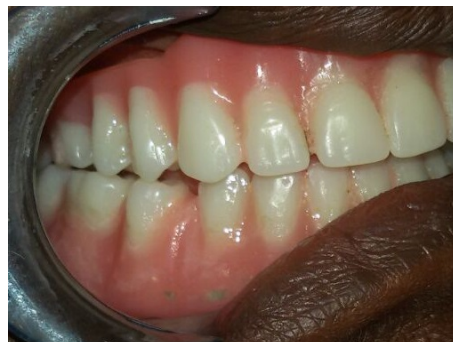Figure 2. Left lateral view.



acrylic (DPI-RR, The Bombay Burmah corporation limited, Mumbai) with correct border extensions. Border molding was done using green stick compound (DPI Pinnacle tracing sticks, The Bombay Burmah corporation limited, Mumbai) and final impressions were made using zinc oxide eugenol impression paste (Neogenate-Sepptodont Health care Pvt. Ltd, Raigad, Maharashtra) with selective pressure technique. To address the retention and stability issues of the denture it was decided to follow the neutral zone technique<sup>4</sup>. Record bases were fabricated using self cure acrylic (DPI-RR, The Bombay Burmah corporation limited, Mumbai). Retentive loops (Figure 4) were fabricated on the lower record base onto which the admixed compound material was adapted<sup>5</sup>. The patient was asked to do all the functional movements according to the neutral zone technique described by Beresin<sup>4</sup> (Figure 5). Occlusal rims were fabricated using the mold obtained by the neutral one technique. Teeth arrangement was done accordingly and the dentures (Figure 6) with some characterizations were fabricated using pink heat cure denture base material (DPI, The Bombay Burmah corporation limited, Mumbai) according to the manufacturer instructions. The dentures were finished and polished and delivered to the patient.

Figure 3. Right lateral view.



Fresh primary impressions of the upper and lower arches were made using impression compound (Y-Dent, MDM Corporation, Delhi), which were poured using dental stone (Kalstone, Kalabhai Karson, Maharashtra). Special trays were fabricated using self cure

Figure 4. Neutral zone technique.

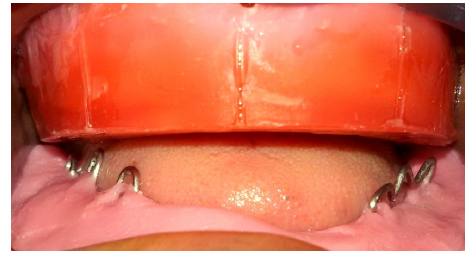


Figure 5. Clear acrylic dentures in mouth.

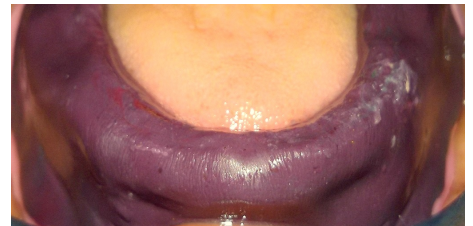
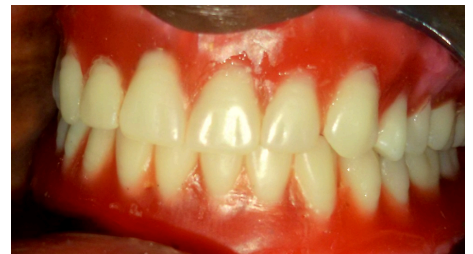
Figure 6. Palatal view.



Though the patient was happy with retention and stability of the new dentures, she still complained of the aesthetics not meeting her expectations. She complained of the dentures being pink in colour which were not matching with her highly melanin pigmented gingival. She requested us if we could replicate the colour of her gingiva as it is. So we decided to use the clear acrylic as final denture base material to address the aesthetic concern along with the neutral zone technique to address the retention and stability issues. So we repeated the above procedure for the patient with only difference of using heat cure clear acrylic as final denture base material (Figures 7 to 9) (DPI, The Bombay Burmah corporation limited, Mumbai).

The patient was finally happy with the aesthetic outcome (Figure 10).

Patient was given home care instructions.

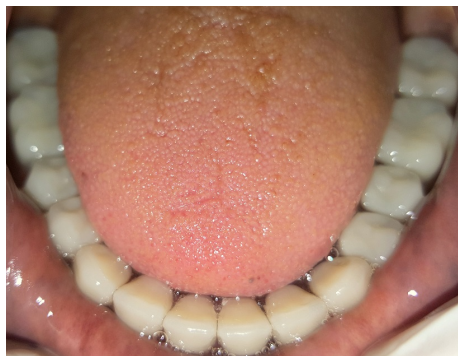
Figure 7. Lower clear acrylic dentures in mouth.

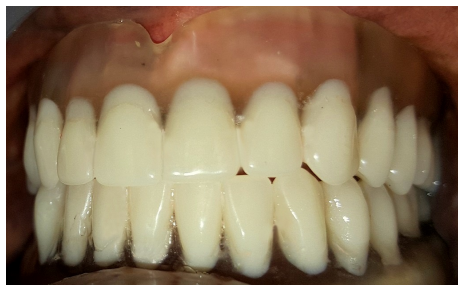

Figure 8. Upper view.

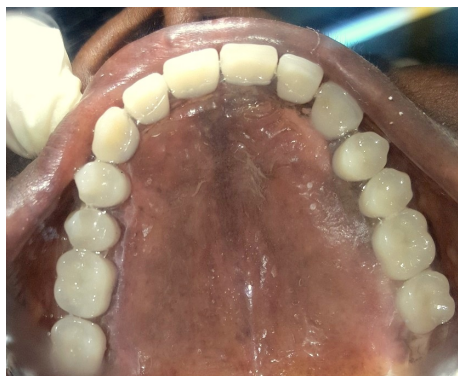

Figure 9. Lower view.



## DISCUSSION

Since 1946, heat cure denture base materials have been used in dentistry. Although it can be cured by ultraviolet and visible light; chemical initiator is commonly used for polymerization. Since the inception, there have been many modifications to improve the physical properties of the Heat cure denture base materials<sup>6</sup>. The various advantages of PMMA are excellent aesthetic properties, adequate

strength, low water sorption, lack of toxicity, facility of repair, and construction by a simple molding and processing technique<sup>7</sup>. Transparent resin is a pure form of PMMA. Hence the properties of the clear acrylic remains as the heat cure denture base material the same except for the pigments used to replicate the gingival colour.

Figure 10. Final aesthetic outcome.



Melanin is the pigment found in the skin of all humans except for when it is pathologically absent. Melanin pigmentation of the intraoral tissues is a relatively frequent finding. And it is observed to be highest at the incisors<sup>8</sup>. Melanin is a complex organic dye which is a product of cell activity and the colour of which varies from bright red and reddish yellow through light and dark brown to black<sup>9</sup>. Gingival pigmentation shade is found to be deeper in Negroes and dark skinned caucasians. Replicating this natural colour in the prosthesis becomes difficult at times when the patient insists. One of the surgical treatment options is gingival depigmentation surgery which all the

patients might not agree to. So the other alternative to rehabilitate the edentulous patient with a conventional denture is to compromise on the physical properties of the high impact denture base material when the aesthetic demand is a priority for the patient. Heat cure clear acrylic is otherwise used to fabricate implant guides, surgical stents, and guiding flanges. The main property of clear acrylic is it is transparent. According to a study done by Duymus et al.<sup>3</sup>, wherein they tested the Vickers hardness of 4 types of denture base materials the heat cure clear acrylic was next only to Heat cure pink acrylic resin. Barclay et al.<sup>10</sup> in 1999 presented a case report where they fabricated a clear acrylic denture because the patient was hyper sensitive to the pink pigment used in the regular heat cure denture base material in. Hence, the use of clear acrylic as a denture base material would be justified if the aesthetic demand is high or in rare cases where the patient is hypersensitive to the pigments used in the regular pink heat cure acrylic. An added advantage in using the clear acrylic denture base is that pressure points underneath the denture can be easily visualized through it which is often difficult or requires additional steps when the pink denture bases are used. However, studies need to be conducted on this material to improve its physical properties so that it could be used as a regular denture material.

## CONCLUSIONS

Rehabilitation of a completely edentulous patient with high aesthetic demand has been presented in this case report. With the ever increasing demand of the patients the dental fraternity faces a challenge on a daily basis. And living up to the expectations of the patients is a great satisfaction in itself. Use of the

clear heat cure acrylic as a permanent denture base material paves an alternative method to satisfy an aesthetically demanding patient as it shows the existing gingival shade. Further studies in this direction are required to improve its physical properties so that this material can be used as a routine denture base material meeting the aesthetic demands of millions.

Brit Dent J 1999;187:350-2.

## REFERENCES

1. Glossary of prosthodontics terms. J Prosthet Dent 2005;94:27.
2. Meshramkar R, Anehosur GV, Pillai LK, et al. Complete denture esthetics revisited. Ind J Oral Sci 2013;4:8-11.
3. Duymusı ZY, Ozdogan A, Ulu H, et al. Evaluation the vickers hardness of denture base materials. Open J Stomatol 2016;6:114-9.
4. Beresin VE, Schiesser FJ. The neutral zone in complete dentures. J Prosthet Dent 2006;95:92-100.
5. McCord JF, Tyson KW. A conservative prosthodontic option for the treatment of edentulous patient with atrophic mandibular ridges. Br Dent J 1997;182:469-47.
6. Anusavice KJ. Phillips science of dental materials. 10th ed. Philadelphia: W.B. Saunders; 1996.
7. Craig RG, Powers JM. Restorative dental materials. 11th ed. Louis: St. Mosby; 2002.
8. Tamizi M, Taheri M. Treatment of severe physiologic gingival pigmentation with free gingival autograft. Quintessence Int 1996;27:555-8.
9. Dummett CO. Physiologic pigmentation of the oral and cutaneous tissues in the negros. J Dent Res 1946;25:421.
10. Barclay SC, Forsyth A, Felix DH, et al. Case report - hypersensitivity to denture materials.