

# NON SURGICAL MANAGEMENT OF LARGE PERIAPICAL LESION USING MTA: REPORT OF 2 CASES

## ABSTRACT

In the past, cases with open apices were often treated over several appointments, using calcium hydroxide, with the hope of creating a “calcific” barrier against which gutta percha could eventually be placed. The treatment could be as long and the prognosis is questionable. These roots were often thinner and, therefore, more brittle; extending treatment over a long period of time without providing a permanent restoration increased the chances of losing these teeth due to fracture. With the favorable histologic response of MTA, this material is the best current choice for this procedure. Completion of these cases in an effective and efficient way allows for permanent restorations to be done in a timelier manner, prolonging the longevity of these teeth. The following case report demonstrates the use of MTA as an obturating material to promote periapical healing with an open apex.

**NOUSHAD, MC\***  
**NIYAZ, Mohammed\***  
**PEEDIKAYIL, Faizal C\*\***  
**PRADEEP, CV\*\*\***  
**SEBASTIAN, Anish\***  
**ARAFATH, Muhammed Yazar\***

## KEYWORDS

MTA. Endodontics. Periapical lesion.

Department of Conservative Dentistry & Endodontics, Kannur Dental College, Anjarakandy, Kannur , Kerala, India\*

Department of Pedodontics, Kannur Dental College, Anjarakandy, Kannur , Kerala, India\*\*

Department of Conservative Dentistry & Endodontics, Yenepoya University, Mangalore, India\*\*\*

## INTRODUCTION

Incomplete root development caused by trauma, caries, or other pulpal pathosis requires special attention and treatment. In such cases, the canal remains large, with thin and fragile walls, and the apex architecture remains divergent. Apexification is an integral part of the treatment of teeth with necrotic pulps with open apices. The aim of apexification is to limit bacterial infection and create an environment conducive to the production of a hard tissue like or apical plug to prevent extrusion of root filling materials.<sup>1,2</sup>

Clinicians have tried several materials to form apical barrier in the past. These include, Calcium hydroxide powder, Calcium hydroxide mixed with different vehicles, Collagen calcium phosphate osteogenic protein, Bone growth factor, Oxidised cellulose and biodentin.<sup>3,4</sup> Deliberate over instrumentation to produce blood clot that induces apical closure has also been described. Calcium hydroxide is considered as the material of choice for this treatment. Clinical studies have shown that the mean time necessary for the formation of an apical barrier with this technique is more than 12 months.<sup>2</sup>

Despite its efficacy, this dressing has several disadvantages, such as variability of treatment time, number of appointments and radiographs, difficulty in patient follow-up, delayed treatment and possibility of an increased risk of tooth fracture after extended

use of calcium hydroxide.<sup>1,4</sup> An alternative for the multi appointment apexification procedure is a single-step technique using Mineral trioxide aggregate (MTA).

Mineral trioxide aggregate (MTA) was developed at Loma Linda University as a root end filling material. MTA has been used for apexification of immature roots instead of  $\text{Ca}(\text{OH})_2$  because of its facilitation of normal peri radicular architecture by inducing hard tissue barriers, MTA apexification may be performed as a one- or two-visit procedure and alleviate the need for extended period of dressing as it is with  $\text{Ca}(\text{OH})_2$ . MTA can be considered a very effective material to promote regeneration of apical tissue, even in infected fully developed teeth with open apices. Therefore the main advantage of this procedure is the high predictability of apical closure with the reduction of treatment time, biocompatibility, less number of appointments and radiographs.<sup>1-7</sup>

Successful prognosis from conservative treatment with MTA would be of great benefit for patients.

## CASE REPORT

### CASE 1:

A 14-year-old male patient presented with a mild swelling at the apical region of his maxillary right central incisor. Radiographic examination revealed an immature tooth with a wide open apex and a radiolucent area

approximately 10x12mm dimension in proximity to the apex of the tooth (Figure 1). Vitality test conducted and the result showed that all upper anterior except both central incisors were vital. After preparing an endodontic access opening a No. 70 gutta-percha point was placed in a butt-to-tip direction, and a periapical radiograph was taken to determine the working length. The root canal was cleaned with a hand file under irrigation with 2.5% NaOCl. The root canal was then dried with sterile paper points. A thick mixture of MTA (MTA-Angelus) was prepared according to manufacturer's instructions and placed to the apical portion of the canal using amalgam carrier and compacted further with the back end of sterilized paper points. The entire root canal was filled with MTA (Figure 2). Finally, the access opening was permanently sealed with a bonded composite resin restoration. The clinical and radiographic follow up upto 9 months showed the patient functioning well with no reported clinical symptoms and an absence of any sinus tract formation. Radiographic evaluation showed healing of periapical lesion at 3, 6, and 9 months (Figure 3, Figure 4, Figure 5).

#### CASE 2:

A 15-year-old boy complaining of severe pain and swelling in his upper right anterior tooth reported to the department of Conservative dentistry and Endodontics. The

patient gave a history of trauma at age 8 and a previous history of endodontic therapy in relation to the same tooth (Figure 6). Radiograph revealed inadequate root canal treatment and thin dentinal walls and an associated periapical lesion. At the first appointment, the obturation material was removed with Hedstrom files (Figure 7) and the working length was determined (Figure 8). After irrigating the canal with 0.5% sodium hypochlorite and saline, Calcium hydroxide was placed as an intracanal dressing. In the subsequent visit, canal was dried with paper points; a master gutta-percha point was made by roll cone technique and adjusted to 3 mm short of the working length. An MTA plug was placed with a MTA carrier and adapted to the apical canal walls using the pre-adjusted gutta-percha point. (Figure 9) The position of the MTA plug was checked radiographically and a wet cotton pellet was placed on top of it before sealing the access cavity with IRM. Lateral compaction of gutta-percha and AH Plus sealer over the set apical MTA was completed at the next appointment 1 week later (Figure 10).

After root canal treatment, post endodontic restoration was done. At 6 months follow-up, radiograph showed successful healing and bone apposition around the M.T.A. material (Figure 11).

Figure 1. Occlusal view of large periapical lesion in relation to incisors.

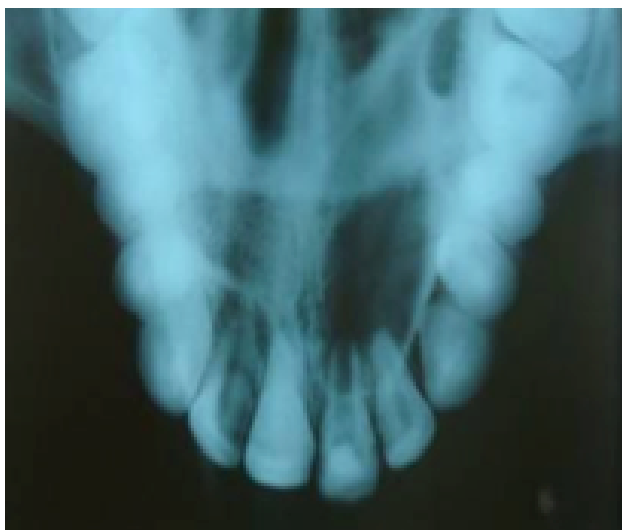

Figure 2. IOPA x-ray showing obturation with MTA.

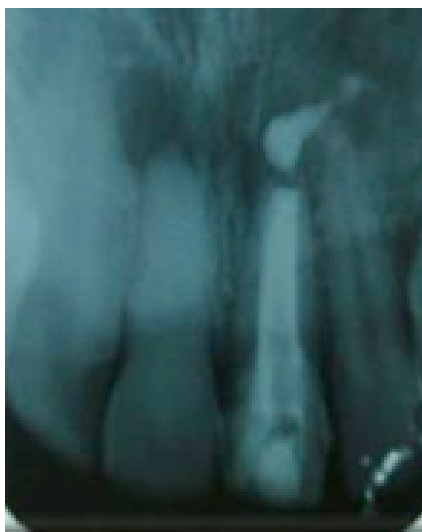

Figure 3. Radiographic evaluation at 3 months showing healing of periapical lesion.

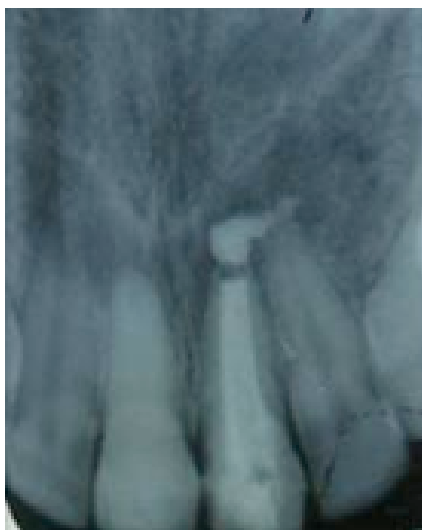

Figure 4. Radiographic evaluation showed healing of periapical lesion after 6 months.

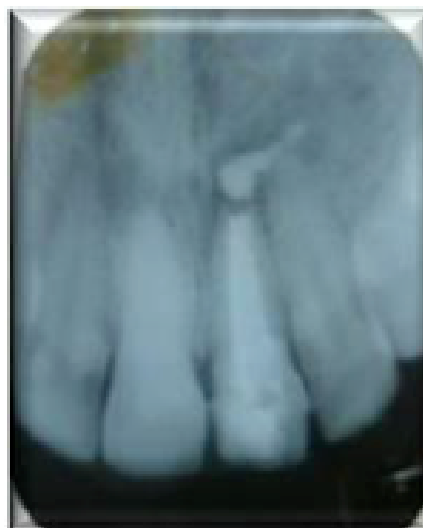

Figure 5. Radiographic evaluation showed healing of periapical lesion after 9 months.

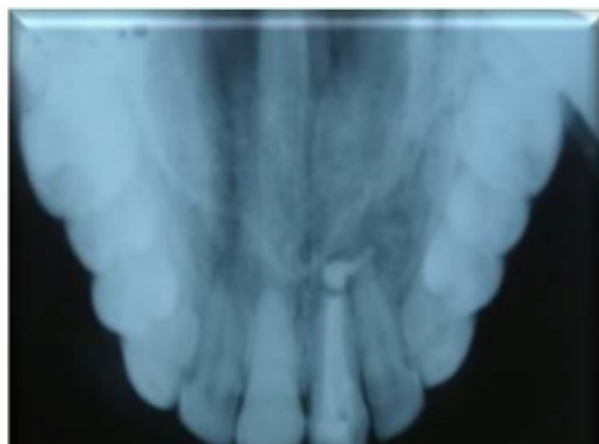


Figure 6. Periapical lesion with inadequately obturated canal.

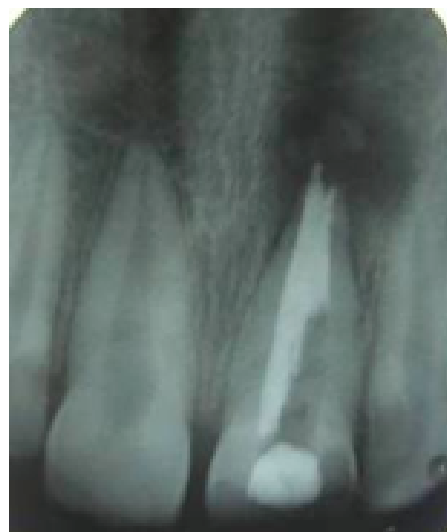

Figure 7. Gutta percha removed from the canal.

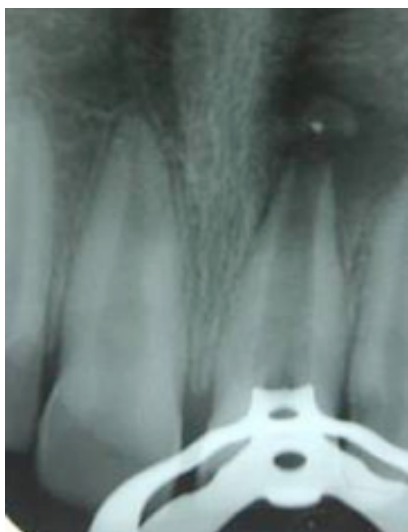

Figure 8. Working length determination.

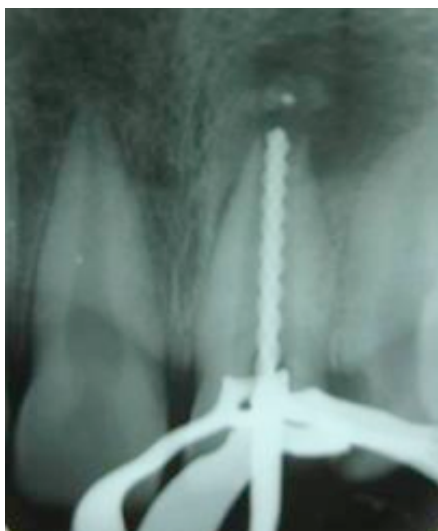

Figure 9. Apical plugging done with Mineral Trioxide Aggregate.

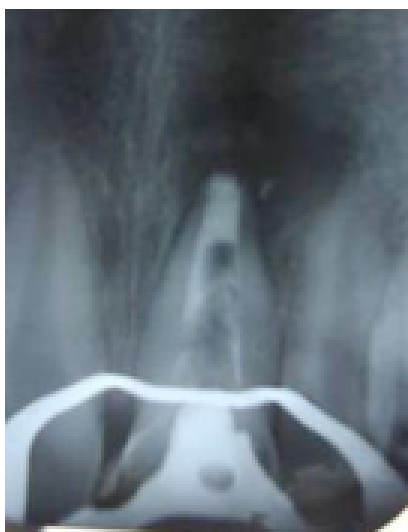

Figure 10. Remaining part of the canal obturated by roll cone technique using gutta percha.

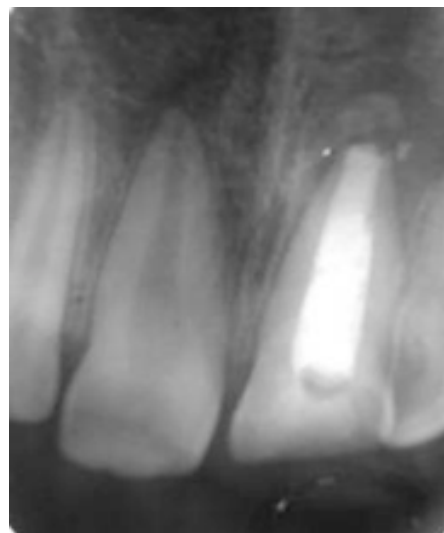
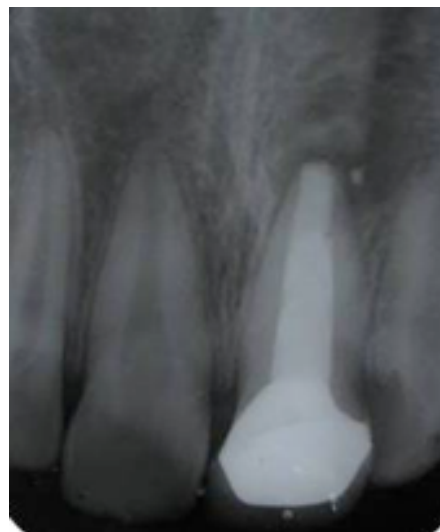

Figure 11. Review after 6 months showing healing of periapical lesion.



## DISCUSSION

Obtaining a successful root end closure is a challenge for the clinician. Even though Calcium hydroxide is commonly used, the latest materials like MTA, biodentine has shown favorable results. Research is going on over the use of materials like Collagen, calcium phosphate, osteogenic protein, Bone growth factor, Oxidised cellulose, etc.<sup>3,4</sup> Failure associated with Calcium hydroxide technique

may be because of repeated overfilling with a high PH material (12.7) which can induce a necrotic zone in the periapical bone or may be lack of proper coronoradicular restoration<sup>3,8</sup>.

Prolonged contact with calcium hydroxide induces a significant decrease in intrinsic properties of the exposed dentin. This factor is directly responsible for many root fracture occurring before the end of the treatment<sup>2,3</sup>. Investigations have been done on Hertwig's epithelial root sheath and cell differentiation during root and apical barrier formation and biologic apical closure appears later i.e. After the filling of root canal.

MTA is endodontic cement that is extremely biocompatible, capable of stimulating healing and osteogenesis, and is hydrophilic. MTA is a powder that consists of fine trioxides (tricalcium oxide, silicate oxide, bismute oxide) and other hydrophilic particles (tricalcium silicate and tricalcium aluminate, responsible for the chemical and physical properties of this aggregate), which set in the presence of moisture. Hydration of the powder results in formation of a colloidal gel with a pH of 12.5.

After drying the canal, the mixed MTA is placed in the canal with a carrier gun and advanced apically with an endodontic plugger, size 9/11, 5/7, 1/3, or a Glick instrument. MTA can be mixed with 0.12% chlorhexidine rather than sterile water or anesthetic solution, which appears to increase its antibacterial properties:

5. The gel solidifies to a hard solid in approximately 3 to 4 hours. This cement is different from other materials currently in use because of its biocompatibility, antibacterial properties, marginal adaptation and sealing properties, and its hydrophilic nature.<sup>1,4,9-15</sup>

According to Economides et al<sup>16</sup>. (2003), MTA is a biocompatible material when used in root-end cavities, stimulating repair of peri radicular tissues, showed no inflammation and the ability of inducing hard tissue formation. MTA has also presented promising outcomes when used for repair of lateral and furcation perforations.

According to Jenkins and Anderson<sup>17</sup> (2012), MTA success in immature teeth with pulp necrosis may be related to a) The extraordinary cementum and periodontal ligament (PDL)-inducing potential of MTA. b) The bacteria tight sealing capacity of MTA when placed in the apical part of the root canal. The combination of a bacteria tight seal in the apical foramen of the root canal and formation of new cementum and PDL make MTA a very biologically acceptable method for closing a root canal with an open apex. MTA releases calcium ions activating cell attachment and proliferation, the high pH creates an antibacterial environment. It also modulates cytokine production and encourages differentiation and migration of hard tissue producing cells and hydroxyapatite is formed

on the MTA surface, and a biologic seal is created.<sup>18</sup>

The material is used for several applications pulp capping, apical surgery and perforation treatment. In all these situations, cell differentiation seems to appear. Felipe et al.<sup>19</sup> (2006) showed that the bridge seems to be formed by bone and not by dentin. MTA has demonstrated good sealability, marginal adaptation and reasonable setting time. And also it can be used in presence of moisture in the root canal. This property is important in teeth with necrotic pulp and inflamed periapical lesion because one of the problems found in these cases is the presence of exudates at the apex of the root. However the application of MTA mixture should be preceded by temporary calcium hydroxide dressing to limit the bacterial infection in the teeth<sup>13-15</sup>.

Obtaining an optimal apical seal in teeth with immature apices is a challenge because the wide apical foramen requires a large volume of filling material that may extrude into the peri radicular tissue initiating the foreign-body reactions. Apical extrusion of the material sometimes occurs. The lack of an apical stop or seat also contributes to the apical extrusion of the material. Special placement techniques, using manual, ultrasonic or ultrasonic-assisted hand delivery for MTA have been suggested to minimize extrusion of the material. Formation of cementum surrounding MTA was observed,

even after extrusion of MTA into a furcation.<sup>13,14</sup>

Studies in dogs and monkeys where MTA is used as an apical plug in showed apical osteitis was induced from a biologic seal and the MTA becomes covered with cementum and a normal PDL attachment.<sup>20</sup> Whereas Calcium hydroxide induces only a cementum like structure at the apex which has numerous vascular channels that could lead to bacterial invasion into these channels perforate it.<sup>21</sup> In a 1 year follow up study to compare Mineral trioxide aggregate with calcium hydroxide, the clinical and radiographic success as a material used to induce root-end closure was 100% for MTA to 86% clinical and radiographic success with calcium hydroxide.<sup>22</sup>

## CONCLUSION

The present case report confirms MTA acts as an apical barrier, not only in apexification cases, but also in failed infected root canal systems. In addition, its superior sealing ability under moist conditions was also an essential requirement for healing in this case.

## REFERENCES

1. Torabinejad M, Hong CU, McDonald F, et al. Physical and chemical properties of a new root-end filling material. *J Endod* 1995;21:349.
2. Chueh LH, Huang GT. Immature teeth with periradicular periodontitis or abscess undergoing apexogenesis: a paradigm shift. *J Endod* 2006;32(12): 1205-13.

3. Wen PH, Liou JU, Duh BR. Apexification of nonvital immature mandibular premolars using two different techniques. *J Dent Sci* 2009;4(2):96–101.
4. Nayak G, Hasan MF. Biodentine- A novel dentinal substitute for single visit apexification. *Restor Dent Endod* 2014 ;39(2):120-25
5. Bogen G, Kuttler S. Mineral trioxide aggregate obturation: A review and case series. *J Endod* 2009;35(6):777-90.
6. Adamo HL, Buruiana R, Schertzer L, et al. A comparison of MTA, SuperEBA, composite and amalgam as root-end filling materials using a bacterial microleakage model. *Int Endod J* 1999;32:197.
7. Krachman SI ,Perforation repair and one step apexification procedures. *Dent Clin N Am* 2004;48:291-307.
8. Torabinejad M, Smith PW, Kettering JD, Pitt Ford TR. Comparative investigation of marginal adaptation of mineral trioxide aggregate and other commonly used root end filling material. *J Endod* 1995;21:295-99.
9. Camilleri J, Montesin FE, Papaioannou S, McDonald F, Pitt Ford TR. Biocompatibility of two commercial forms of mineral trioxide aggregate. *Int Endod J* 2004;37:699-704.
10. Torabinejad M, Chivian N. Clinical applications of mineral trioxide aggregate. *J Endodontics* 1999;25:197-205.
11. Dreger LA, Felipe WT, Reyes-Carmona JF, Felipe GS, Bortoluzzi EA, Felipe MC. . Mineral trioxide aggregate and Portland cement promote biomineralization in vivo. *J Endod* 2012;38(3):324-9.
12. Masuda YM, Wang X, Hossain M et al. Evaluation of biocompatibility of mineral trioxide aggregate with an improved rabbit ear chamber. *J Oral Rehabil* 2005;32(2):145–50.
13. Simon S, Rilliard F, Berdal A et al. The use of mineral trioxide aggregate in one-visit apexification treatment: a prospective study. *Int Endod J* 2007;40(3):186-97.
14. Scarparo RK, Haddad D, Acasigua GA. Mineral trioxide aggregate-based sealer: Analysis of tissue reactions to a new endodontic material. *J Endod* 2010;36(7):1174-78.
15. Gomes-Filho JE, Watanabe S, Lodi CS, Cintra LTA, Nery MJ, Filho JAO, et al. Rat tissue reaction to MTA Fillapex ®. *Dent Traumatol* 2012 Dec;28(6):452-56.
16. Economides N, Pantelidou O, Kokkas A, Tziafas D. Short-term periradicular tissue response to mineral trioxide aggregate (MTA) as root-end filling material. *Int Endod J* 2003 Jan;36(1):44-8.
17. Bakland LK, Andreasen JO. Will mineral trioxide aggregate replace calcium hydroxide in treating pulpal and periodontal healing complications subsequent to dental trauma? A review. *Dent Traumatol* 2012;28:25-32.
18. Parioikh M, Torabinejad M. Mineral trioxide aggregate: a comprehensive literature review-part I: chemical, physical, and antibacterial properties. *J Endod* 2010;36:16–27.
19. Felipe WT, Felipe MC, Rocha MJ. The effect of mineral trioxide aggregate on the apexification and periapical healing of teeth with incomplete root formation. *Int Endod J* 2006 Jan;39(1):2-9.
20. Shabahang S, Torabinejad M. Treatment of teeth with open apices using mineral trioxide aggregate. *Pract Periodontics Aesthet Dent* 2000;12:315-21.
21. Cvek M, Sundström B. Treatment of non-vital permanent incisors with calcium hydroxide. *V.*



Histologic appearance of roentgenographically demonstrable apical closure of immature roots. *Odontol Revy* 1974;25:379-92.

22. El-Meligy OA, Avery DR. Comparison of apexification with mineral trioxide aggregate and calcium hydroxide. *Pediatr Dent* 2006 May-Jun;28(3):248-53.