

# ODONTOGENIC MYXOMA IN CHILDREN: CASE REPORT

## ABSTRACT

Odontogenic myxoma is a rare tumor, often diagnosed during routine radiographs or when it is so severe that it causes pain, a noticeable increase in volume or tooth displacement and mobility. Young adults (25-30 years of life) are more often affected by the lesion but all ages are vulnerable. The mandible is more commonly involved than the maxilla and the tumors usually grow slowly and silently. However, growth can be rapid and destructive. The radiographic aspect of a myxoma is that of a uni or multilocular, radiolucent lesion reminiscent of honeycomb or soap bubbles, depending on its size. It is an expansive tumor that may cause displacement or resorption of the teeth involved. Microscopically, the tumor is composed of round and spindle cells, with a star arrangement, arranged in a loose abundant myxoid stroma, containing only a few collagen fibrils. The treatment of choice is radical surgical excision because myxomas are not encapsulated and tend to infiltrate the surrounding bone. However, small tumors can be treated by curettage. Periodic reassessment is required for at least five years due to the high rate of recurrence. Larger tumors may need to be treated using a more extensive resection with a safety margin. This study reports a clinical case of odontogenic myxoma in a child aged 7 years. The tumor was located in the posterior region of the mandible and was surgically treated with an en bloc resection with preservation of the base of the mandible. The follow-up of the case is ongoing and no recurrence has been observed to date.

**NAVES NETO**, Valdor Araujo\*

**SARTORI**, Ivete Aparecida de Mattias\*\*

**OLIVEIRA**, Laudimar Alves\*\*\*

**BUGARIN JÚNIOR**, João Geraldo\*

**SOUZA**, Danilo Sérgio Carvalho\*\*

**CARDOSO**, Frederico Rodger Rodrigues Gomes\*\*

**COUTINHO**, Helio\*\*\*\*

## KEYWORDS

Odontogenic myxoma. Odontogenic tumor. Oral pathology.

Department of Implantology, Paulista University, Brasília, DF, Brazil\*

Latin American Institute of Dentistry Research and Education, Curitiba, PR, Brazil\*\*

University of Brasília, Brasília, DF, Brazil\*\*\*

Support Group Apprentices Christian Love, Brasília, DF, Brazil\*\*\*\*

Correspondence: gaaac1@gmail.com (COUTINHO H) | Received 07 Aug 2014 Received in revised form 19 Aug 2014 Accepted 24 Aug 2014

## INTRODUCTION

Maxillary myxomas are tumors that originate from the odontogenic ectomesenchyme. Microscopically they resemble the mesenchymal portion of a developing tooth, pulp connective tissue or, more primitively, a dental follicle or dental papilla<sup>1,2</sup>. Radiographically they appear as uni or multilocular radiolucent lesions with an aspect that can be described as soap bubbles and/or honeycomb, according to the size of the loculations<sup>1,2,3</sup>.

The most affected patients are young adults, aged between 25 to 30 years, but this tumor can occur in any age group. There is no predilection for gender and the tumors can be found in all regions of gnathic bones, although the mandible is slightly more affected than the maxilla<sup>1,2,3</sup>.

Usually, odontogenic myxoma is a benign tumor that is asymptomatic; however, some cases may be aggressive and infiltrative, with associated symptoms. Because of the gelatinous and loose consistency of the tumor tissue, high recurrence rates are observed. Thus, a simple curettage of the tumor may result in its incomplete removal; therefore, surgical excision is the preferred treatment<sup>1,2,3</sup>.

The aim of this report was to present the clinical case of an odontogenic myxoma in the posterior region of the mandible in a seven-year-old child treated surgically with en bloc resection in which the base of the

mandible was preserved.

## LITERATURE REVIEW

Maxillary myxomas are benign tumors of odontogenic origin<sup>1</sup>. They consist of regular round and spindle cells, with a star arrangement, in a loose abundant myxoid stroma, containing few collagen fibrils. Rare cases have marked cellular atypia and are, therefore, called myxosarcomas. These tumors appear to have a more aggressive course than myxomas; however, distant metastases have not been reported for either type of tumor.

Most cases of odontogenic myxoma clinically present as volumetric increases with ill-defined borders and varying consistency. The tumor surface is generally intact and has a color similar to the mucosa or whitish. In some cases, the surface may be ulcerated due to masticatory trauma<sup>3,4,5,6</sup>.

Most tumors cause dental mobility or displacement and root resorption may also be present. Generally, the tumor is asymptomatic, but it is not unusual for pain to be a striking symptom, which leads the patient to seek dental care<sup>3,4,5,6,7</sup>.

Odontogenic myxoma can be observed in any region of the maxillary bones. However, there is a higher prevalence of tumors in the mandible<sup>1,2,8</sup>. Melo filho & Martins<sup>9</sup> showed that there was a higher prevalence of mandibular tumors (56.56%) compared with

maxillary tumors (42.18%), with a mandible:maxilla ratio of 1.34:1. Likewise, Nonaka<sup>10</sup> reported greater mandibular involvement (57.14%) than maxillary (35.71%).

Mata<sup>6</sup> also found a higher prevalence of mandibular tumors (59.6%) compared with maxillary tumors (40.4%). Regarding the involvement of the anterior and posterior regions of the gnathic bones, the authors observed a higher incidence in the posterior region of the mandible (35.5%) and also in the posterior region of the maxilla (21%). Also in 2007, Nonaka<sup>10</sup> showed a higher prevalence of lesions in the posterior region of the maxillary bones (64.29%).

Odontogenic myxoma presents as a uni or multilocular radiolucent lesion, which can cause displacement and resorption of the teeth that are involved. The size of the tumor can vary, and multilocular tumors are generally larger than unilocular ones.<sup>3,6</sup>

The margins of the lesion are often irregular or scalloped and thin trabeculae of radiopaque bone can be observed inside the mass, arranged at a right angle. Larger tumors may present as an image resembling soap bubbles, similar to the radiographic aspect of a multilocular ameloblastoma, keratocyst, central giant-cell tumor or odontogenic fibroma. This multilocular pattern of smaller tumors is called "honeycomb".<sup>1-4,9</sup>

The tumors are always radiolucent, although the radiolucency pattern can be highly variable.<sup>6</sup> Sometimes they are well defined, other times they are diffuse. The expansion of the cortical bone due to the tumor is more frequent than its perforation. Likewise, root displacement is more commonly observed than root resorption.<sup>1,2,5</sup> In maxillary tumors, there is often maxillary sinus invasion, due to the tumor's infiltrative nature.<sup>8,11</sup>

Odontogenic myxoma has a loose and gelatinous structure. Microscopically this structure is composed of round and spindle cells with a star arrangement, which consists of benign myofibroblasts and fibroblasts, arranged in an abundant myxoid stroma, containing only a few collagen fibrils. There is rich loose myxomatous connective tissue in the mucopolysaccharides matrix. Some tumors have a tendency to produce collagen and are, therefore, called fibromyxomas.<sup>1-6,8,9,11</sup>

Fusiform and loosely arranged stellate cells can present long fibrillar processes with a tendency to form a network. The soft tissue is not excessively cellular, and the existing cells show no evidence of significant activity (pleomorphism, prominent nucleoli or mitotic figures). Small islands of odontogenic epithelial rests, apparently inactive, may be dispersed in the myxoid ground substance, as well as bone islets consisting of residual trabeculae, irregular foci of calcification, and minuscule blood capillaries.<sup>1-5,8,9,11</sup>

Surgical excision is the treatment of choice for odontogenic myxomas. Due to its gelatinous and loose consistency, curettage may result in incomplete removal of the neoplasm. Furthermore, when the tumor is treated in a conservative manner, the absence of the capsule can also hinder its complete excision.<sup>2,3</sup>

According to Melo Filho & Martins<sup>9</sup> the best forms of treatment are: enucleation, curettage, peripheral block resection and wide resection. They are of the opinion that smaller tumors should be treated with enucleation and meticulous curettage, with periodic follow-up. Large tumors require more invasive resections, which should be repaired in the best possible way. According to the authors, the more aggressive the surgery, the lower the recurrence rate.

All forms of treatment should attempt to minimize the psychological impact on the patient, minimize any aesthetic or functional impairment and prevent relapses, as one of the roles of a dentist is to ensure the welfare and quality of life of patients.<sup>9</sup>

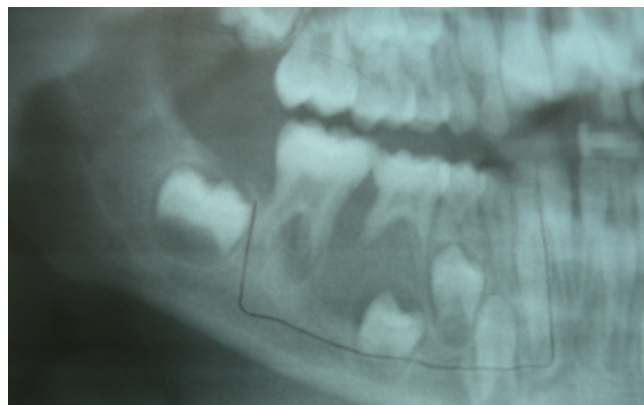### CLINICAL CASE REPORT

Patient A.F.L., 07 years old, female, Caucasian, a resident of Unaí, Minas Gerais, attended a private clinic complaining of volumetric increase in the lingual region of the right side of the mandible. During the initial consultation, a panoramic (Figure 1), an

occlusal (Figure 2) and a periapical radiograph (Figure 3) of the region were requested. The patient was then referred to the outpatient clinic of GAAAC (Support Group Apprentices Christian Love) for evaluation.

At GAAAC the patient underwent an extra-oral clinical examination where a small amount of facial asymmetry was observed on the right side of the face. In the intra-oral clinical examination a large volumetric increase in the lingual region of the mandible was observed. It was approximately 3 cm at its largest diameter, and had caused the displacement of the primary and permanent molars (Figure 4).

Figure 1. Panoramic radiograph - area of the tumor and demarcation of the resection surgery.



The radiographic examination revealed an extensive multilocular radiolucent area with ill-defined borders, extending from the region of the first lower permanent molar to the lower right primary canine. The tumor involved the periapical region of the above-mentioned teeth and extended towards the

base of the mandible (Figure 1 and 3). There was no expansion of the lingual or buccal mandibular bone (Figure 2).

Figure 2. Occlusal radiograph - Buccal and lingual cortical bone without expansion.

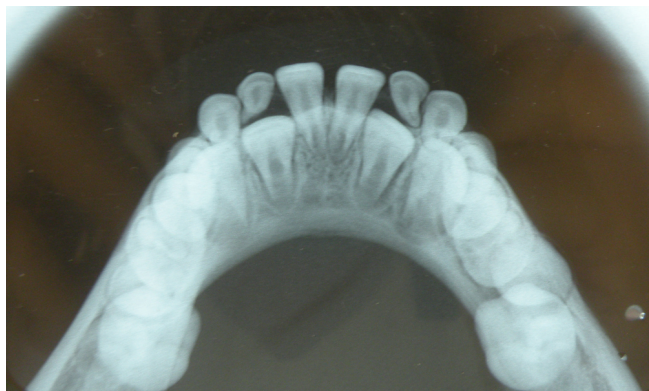
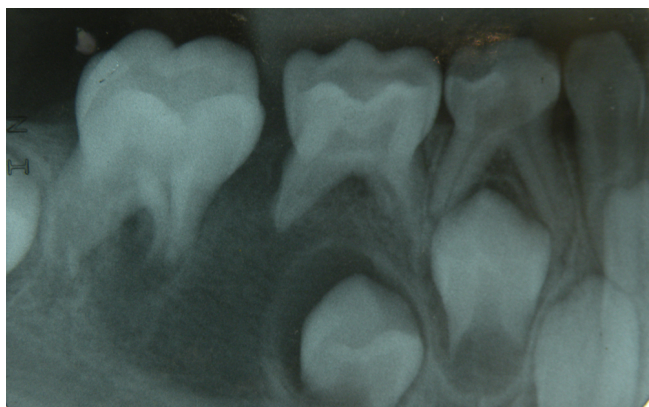


Figure 3. Periapical radiograph - multilocular aspect of the tumor and involvement of the primary teeth and germs of the permanent teeth.

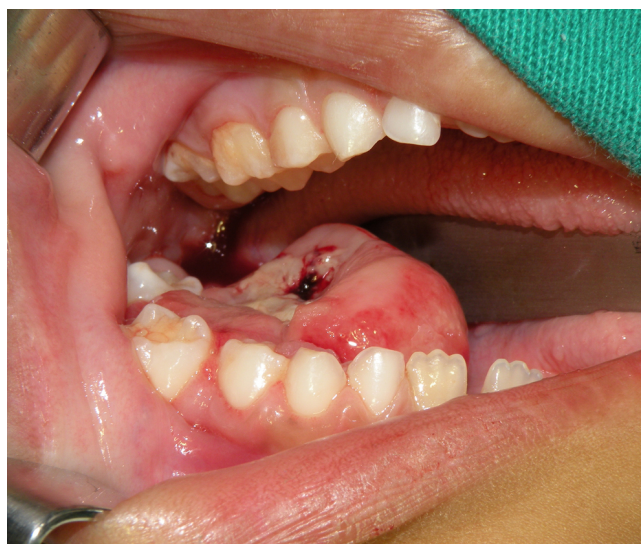

An incisional biopsy was carried out under local anesthesia. The removed material underwent a pathological analysis to verify the clinical diagnosis hypothesis of odontogenic myxoma.

Microscopically, the tumor presented as a spindle cell neoplasm with myxoid stroma without cellular atypia or mitotic figures, which confirmed the diagnosis of odontogenic myxoma. Preoperative test results were within

the normal range. The patient then underwent surgery using general anesthesia and nasotracheal intubation.

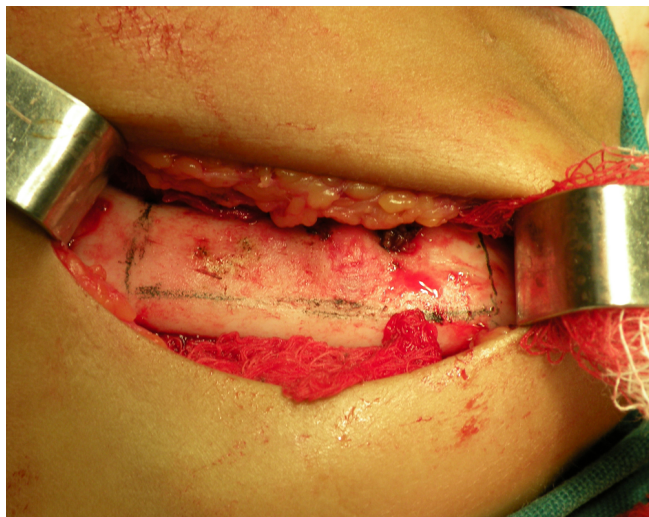
Figure 4. Intraoral aspect of the tumor.



The demarcation of the extra-oral incision extended approximately from the region of the lower right primary lateral incisor to the area of the lower right permanent first molar. The infiltration for anesthesia and hemostasis was carried out with bupivacaine with vasoconstrictor (Cristália, Itapira, Brasil), followed by incision of the planes, initially through the epithelial tissue, which was divulsed to expose the adipose tissue. The adipose tissue was then separated from the muscular plane in order to enable a clear view of the platysma and masseter muscles. A new incision was then made on the muscular plane, in order to reach the bone plane and also the periosteum. The bone resection region was then demarcated, but the base of the mandible was preserved in

order to minimize facial asymmetry and interference with bone growth, since the patient was a child (Figure 5).

Figure 5. Buccal bone plate and demarcation of resection in the mandible.



The osteotomy of the region extended from the first permanent right mandibular molar to the right primary mandibular canine and also involved the removal of the tooth germs of the canine, first and second premolar and second molar, which were in the resection area. The entire procedure was carried out using a surgical conical bur and irrigated with saline. The detachment of the bone block was carried out using two straight Wagner chisels.

Afterwards, an intraoral extensive incision was carried out to allow the complete and safe removal of the tumor (Figure 6 and 7).

The bone was smoothed using a "Maxicut" type bur and electrocautery was carried out. The unaffected area of the

mandible had no visible pathological alterations.

Figure 6. Exeresis of the tumor.

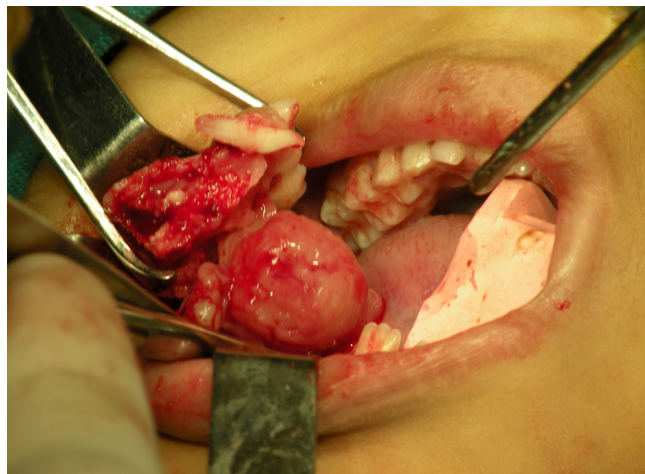
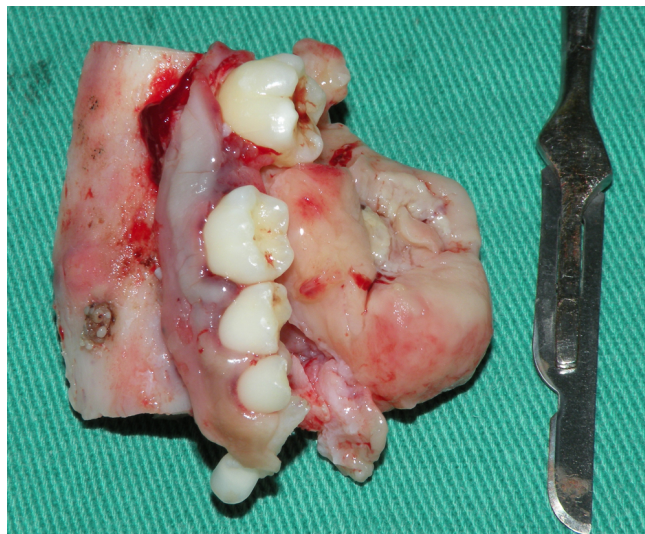


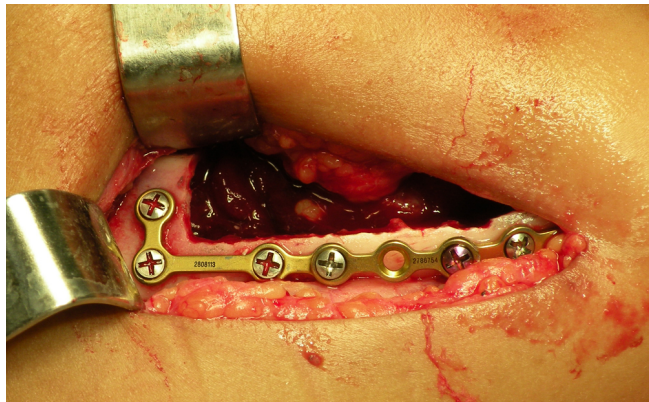
Figure 7. Macroscopic aspect of the tumor, 3 cm at its largest diameter.



Plates and screws were used to fix the mandible in an attempt to avoid possible fractures because the patient was a child. Three system 2.0 (neortho, Curitiba, Brasil) plates were fixed. Two L-shaped plates were attached to the periphery, and one straight plate was fixed at the base of the mandible overlapping the L-shaped plates, Figure 8). All

of the plates and screws that were used were donated by the manufacturer.

Figure 8. Fixation of the plates and screws.



Nylon 3-0 was used for the synthesis of the intraoral area. In the extra-oral region, 5-0 Vicryl absorbable suture was used for the synthesis of the muscular plane and 5-0 nylon monofilament for the epidermis and dermis. The patient was discharged twenty-four hours after surgery with moderate edema in the operated area. In the immediate postoperative period, panoramic radiography was carried out and good adaptation of the plates and screws was observed and there were no signs of the tumor (Figure 9).

The patient was evaluated weekly in the first three months after surgery. At the time of writing the follow-up was being carried out every two years. The patient has presented good healing and minimal facial asymmetry (Figures 10 and 11). No clinical recurrence of the tumor has occurred.

Figure 09. Panoramic radiograph taken at the immediate postoperative period - Good adaptation of plates and screws.

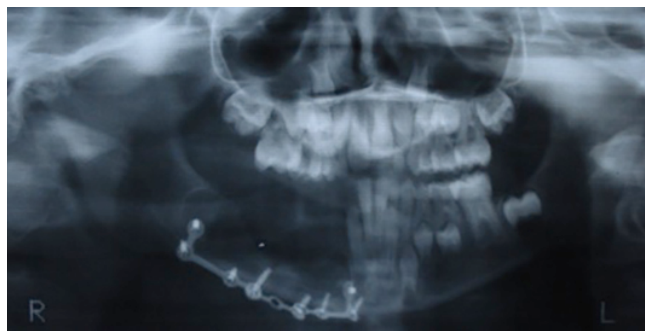


Figure 10. Aspect of the intra-oral tissue seven months after surgery.

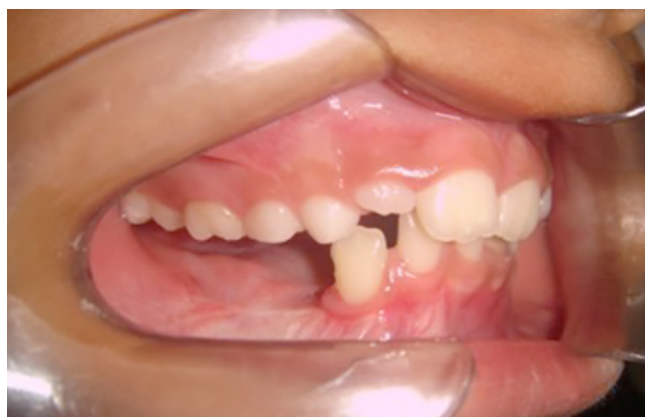
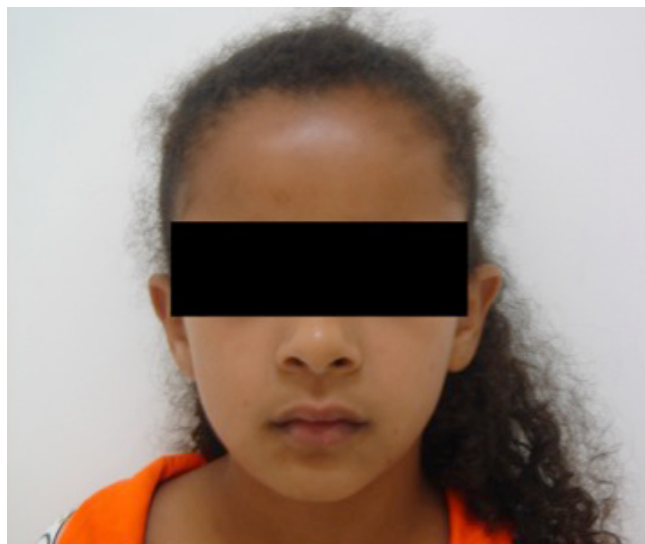
Figure 11. Slight asymmetry of the face, seven months after surgery.



## DISCUSSION

This type of tumor is most prevalent between the third and fifth decades of life.<sup>1-3,8,10</sup> The involvement of children is rare, especially in individuals under the age of 10 years, as in the present case.<sup>12-16</sup>

Although some authors<sup>1,2,8,10</sup> such as have described a similar prevalence between genders, some studies have shown a higher prevalence of odontogenic myxomas among women, which corroborates our finding.<sup>3,9,17,18</sup>

The mandible is more commonly affected than the maxilla, and the posterior region of both gnathic bones is the most affected area.<sup>1,2,8-10</sup> In the case described, the tumor has similar characteristics to those described in the literature, although Rotenberg<sup>17</sup> reported a higher prevalence of odontogenic myxoma in the maxilla in the case of children.

The radiographic aspect of the multilocular and radiolucent tumor observed in the case described is similar to the typical soap bubbles described in the literature.<sup>1-4,8,9</sup> Although they are not pathognomonic, these findings help to make the differential diagnosis between odontogenic myxoma and other tumors, such as ameloblastoma, keratocystic odontogenic tumor, central giant-cell granuloma or odontogenic fibroma.<sup>1,2,4,9</sup> In this case, these were some of the diagnostic hypotheses that were initially proposed.

Microscopically, the tumor in this case study was a cluster of fusiform and stellate cells arranged in a loose myxoid ground substance, with capillary vessels. These histopathological findings enabled us to confirm the diagnosis in line with the literature.<sup>1-5,8,9,11</sup>

According to the authors,<sup>1,2,8,9</sup> treatment ranges from enucleation to extensive resection of the affected area, depending upon the size of the tumor and the risk of relapse. In this case, the patient was just 7 years old, so even though she had a large tumor, we opted for a more conservative treatment, with resection of the affected region preserving the unaffected base of the mandible. The area was also cauterized in line with Shafer.<sup>8</sup>

## CONCLUSION

Although rare, odontogenic myxomas are tumors that should be considered in the differential diagnosis of multilocular radiolucent lesions in children.

En bloc resection with preservation of the base of the mandible is a good alternative treatment, causing little facial asymmetry and the least harm to the patient.

The prognosis of the case was favorable because there has been no clinical recurrence to date.

Forms of treatment that aim to improve the quality of life of patients should be



considered in all cases, always taking into account the risk of relapse.

The most conservative treatment facilitates rehabilitation and interferes less in the quality of life of patients after surgery, although it has a higher risk of relapse.

### REFERENCES

1. Neville BW, Damn DD, Allen CM, Bouquot JE. *Patologia oral e maxilofacial*. 3°. ed. Elsevier Editora: Rio de Janeiro, 2009.
2. Regezi JA, Sciubba JJ, Jordan RCK. *Patologia oral - Correlações clinicopatológicas*. 5°. ed. Elsevier Editora: Rio de Janeiro, 2008.
3. Barnes L, Eveson JW, Reichart P, Sidransky D. *World Health Organization Classification of Tumours. Pathology and Genetics of Head and Neck Tumours*. IARC Press: Lyon, 2005.
4. Castro AL, Kanno CM, Callestini R, Sicchieri LG, Munhoz FC. Mixoma odontogênico em mandíbula. *Rev Odontol Araçatuba* 2003;24(2):23-27.
5. Correia AVL, Amaral MF, Falcão MFL, Szyfer SBO, Castro JFL. Mixoma odontogênico mandibular: relato de caso. *Int J Dent* 2008;7(3):194-198.
6. Mata GM, Taylor AM, Bregni RC, Almeida OP, Vidaurre EC, Valdez AC, Malagón HD. Odontogenic myxoma: Clinico-pathological, immunohistochemical and ultrastructural findings of a multicentric series. *Oral Oncol* 2007.
7. Melo AUC, Martorelli BF, Cavalcanti PHH, Gueiros LA, Martorelli FO. Mixoma odontogênico maxilar: relato caso clinico comprometendo seio maxilar. *Rev Bras Otorrinolaringol* 2008;74(3):472-475.
8. Shafer WG, Hine WK, Levi BM. *Tratado de patologia bucal*. 4°. ed. Editora Guanabara Koogan: Rio de Janeiro, 1987.
9. Melo Filho MR, Martins CR. Mixoma Odontogênico: revisão da literatura e análise de 320 casos quanto ao sexo, localização e idade. *Científ* 2001;1(1).
10. Nonaka CFW, Cavalcante RB, Piva MR, Souza LD, Pinto LP. Mixoma Odontogênico: estudo clinico-patológico de 14 casos. *Cienc Odontol Bras B* 2007;10(2):61-67.
11. Vers Filho RO, Pinheiro SS, Almeida ICP, Arruda MLS, Costa ALL. Mixoma odontogênico em maxila com invasão em seio maxilar. *Rev Bras Otorrinolaringol* 2008;74(6):945.
12. Dezotti MS, Azevedo LR, Fontão FN, Capelozza AL, Sant'ana E. Odontogenic myxoma- a case report and clinico-radiographic study of seven tumors. *J Contemp Dent Pract* 2006;7(1):117-24.
13. Harokopakis-Hajishengallis E, Tiwana P. Odontogenic myxoma in the pediatric patient: a literatura review and case report. *Pediatric Dent* 2007;29(5):409-414.
14. Keszler A, Dominguez F, Giannunzio G. Myxoma in childhood \*1An analysis of 10 cases. *J Oral Maxillofac Surg* 1995;53:518-521.
15. Moussa A, Achach T, Njim L, Yahia NB, Gassab E, Zakhama A. Odontogenic myxoma: A report of an unusual pediatric case. *int J Ped Otorhinolaryngol* 2007;2:173-175.
16. Rotenberg BW, Daniel SJ, Nish IA, Ngan BY, Forte V. Myxomatous lesions of the maxilla in children: a case series and review of management. *Int J Pediatr Otorhinolaryngol* 2004;68(10):1251-14.

17. Noffke CE, Raubenheimer EJ, Chabikuli NJ, Bouckaert MM. Odontogenic myxoma: review of the literature and report of 30 cases from South Africa. *Oral Surg Oral Med Oral Pathol Radiol Endod* 2007;104(1):101-9.

18. Sloomweg PJ, Wittkamp K. Myxoma of the jaws. An analysis of 15 cases. *J Maxillofac Surg* 1986;14:46-52.