

PREVALENCE OF MANDIBULAR ASYMMETRY IN SKELETAL CLASS I ADULT PATIENTS

ABSTRACT

AIM: The objective of this study was evaluating the prevalence of mandibular asymmetry in skeletal Class I adult patients.

MATERIALS AND METHODS: The sample was composed by cone-beam computed tomography images of 250 skeletal Class I patients with age from 18 to 70 years old. The side deviation of mandibular asymmetry was evaluated (right and left), as well as the intensity of this asymmetry. People with gnathic deviation until 2mm were considered as patients with slight asymmetry; deviation between 2 and 5mm was considered moderate asymmetry and those higher than 5mm as severe asymmetries. The error calculation method was performed and there was not significant error in the measurements. To verify the association between the prevalence of mandibular asymmetry and the gender of individuals, the X^2 was carried out and the significant level adopted was 5% ($p < 0.05$).

RESULTS: The results showed that mandibular deviation occurred more frequently to the left side in both genders (male 56.5% e female 58.2%), without statistically significant difference between them ($p = 0.792$). Besides, the prevalence of slight, moderate and severe asymmetries were, respectively 61%, 27% and 12% for males and 54%, 28% and 18% for female; and there was not statistically significant difference ($p = 0.366$) between the gender of the sample evaluated. **CONCLUSION:** In this study, both deviation and intensity of mandibular asymmetry did not present preference regarding to the gender.

GRIBEL, Bruno Frazão*

THIESEN, Guilherme**

BORGES, Tássia Silvana***

FREITAS, Maria Perpétua Mota****

KEYWORDS

Facial Asymmetry. Orthodontics. Orthognathic Surgery.
Cone-Beam Computed Tomography.

Master in Orthodontics by Pontifical Catholic University of Minas Gerais, Minas Gerais, Brazil*

Student of Doctor Degree in Orthodontic (emphasis in Orthodontics) at Lutheran University of Brazil, Brazil**

Student of Master Degree in Orthodontics (emphasis on Pediatric Dentistry) at Lutheran University of Brazil, Brazil***

Professor of the Graduation and Post-Graduation Program in Orthodontics at Lutheran University of Brazil, Brazil****

Correspondence: guilhermethiesen@yahoo.com.br (THIESEN G) | Received 10 Feb 2014 Received in revised form 15 Feb 2014 Accepted 24 Feb 2014

INTRODUCTION

Facial alterations in anteroposterior and vertical dimensions have been widely investigated in Orthodontics; however, few have been examined about changes craniofacial symmetry in front view^{1,2}.

It is known that absolute bilateral symmetry is an uncommon beauty pattern in the nature, and thus, the expectation about the two halves is the balance. Therefore, small differences between right and left sides are expected and considered as normal. In almost every person is found a slight degree of facial asymmetry that might be imperceptible, even during a closer observation. It is due to the fact that the face, in its middle and inferior third, has development from the medial nasal, lateral nasal, maxillary and mandibular; despite the intrinsic coordination of these structures, failures or defects in development and maturation of these embryonic processes can occur. Thereunto, facial asymmetry is consequence of disordered growth of craniofacial structures, and may be triggered by genetic factors, congenital malformation, environmental factors like habits and/or trauma and functional deviation, which can compromising the maxillary and mandibular growth^{3,4}.

Facial asymmetry of soft tissue is commonly arising from one asymmetry present in the support skeletal tissue, thus resulting in aesthetical asymmetries in the

face. Patients orthodontically treated present prevalence of asymmetry in 34%, and the mandibular deviation is the most remarkable characteristic in this asymmetry⁵.

Facial asymmetry in a severe degree further compromise aesthetically, can also affect the function. Dental asymmetries and a variety of functional deviations can be treated orthodontically. However, significant structural facial asymmetries are not easily hidden by orthodontic treatment. These problems may require orthopedic correction during the growth stage, and/or orthognathic surgery in the adult stage. It does not seem clear the limit between “acceptable” and “unacceptable” for face asymmetries, and this limit does not seem to be simple to establish. However, some studies have searched determine the correlation between the clinical facial asymmetry and the skeletal asymmetry of patients, and then quantify from how many millimeters of deviation this asymmetry becomes perceptible⁴.

According with some authors, the clinical expression of asymmetry only occurs when the bone deviation is, at least, 4 or 5mm^{3,4,6,7,8}. Under this value, the asymmetry is considered subclinical. In other words, the human sensitivity to realize severe unbalances in the face occurs easily when the asymmetry is near or higher than 5mm^{2,9,10}. However, the expression of asymmetry or its masking will depend on individual characteristics, like the

thickness of the soft tissue over the unbalanced region. In this way, other authors consider asymmetric face when occurs bone deviation from 2mm^{11,12,13,14}. The most of these works evaluate the skeleton deviation from gnathic or menton displacement in relation to the vertical midline of the face. It is because the jaw is the main contributor to the dentofacial asymmetry, and most of maxillary asymmetries is secondary to the asymmetric mandibular growth^{10,13,15}.

The recent arisen of cone-beam computed tomography (CBCT) allows the reconstruction of bi-dimensional and tridimensional images, further reconstructions in other plans (axial, sagittal and coronal). Thereunto, the image from CBCT makes possible a reliable measure of the entire craniofacial region with no distortions and increase the confidence in diagnosis¹⁶.

Regarding to this theme, the aim of this work is determine, by CBCT, the prevalence of mandibular asymmetry in adult patients with sagittal skeletal growth pattern Class I.

MATERIALS AND METHODS

The sample was composed by CBCT images of 250 patients, which belong to the collection of a central diagnostic services and dental plan (Compass3d in Belo Horizonte – MG, Brazil). These tomographic images were carried out in these patients with therapeutic diagnosis aims from 2012 to 2013. To perform

these tests, all the patients in this sample used a tomography device brand i-CAT (Imaging Sciences International, Hatfield, Pa). This apparatus was adjusted to operate according to the following specifications: 120KvP, 8mA and exposition time of 20 seconds. The patients were oriented to stay sat down in the device with the head positioned with the Frankfurt plan, parallel with the ground, and median sagittal plane perpendicular to the ground. The images from the cone beam computed tomography were acquired in DICOM (Digital Imaging and Communication in Medicine) format. The images from the CBCT stored in DICOM format allowed perform measurements with the VistaDent 3D 2.1 (GAC Dentsply, New York, USA). The software is able to perform measures both according to the volume (mm³), and the surface (mm²) through quantification of voxels present in the bone images, and posteriorly provide exact values of the studied structures.

The sample selection considered only adult patients with skeletal Class I from 18 to 70 years old, with random choice regarding to the gender and race. These patients must present all the permanent teeth erupted until the first molars. Exclusion criteria were determined by the absence of previous history of fracture in the face region, syndromes and craniofacial anomalies.

The reference points and plans used for tomography measurement were the following:

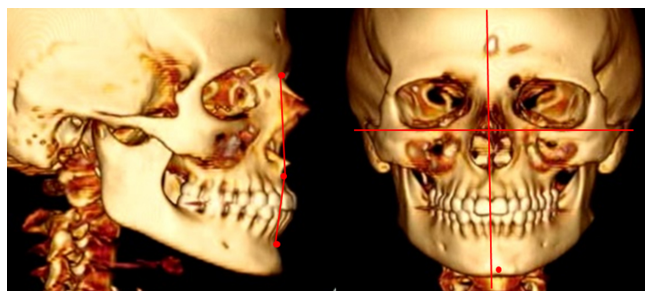
Point A (subspinal): point localized in the bigger concavity of anterior maxillary portion; Point B (supramenton): point localized in the bigger concavity of anterior mentonian symphysis portion; Point N (nasion): most anterior and medial point of frontonasal suture; Point Ba (basion): medial point over the anterior edge of the occipital foramen; Point Po (anatomical porion): most superior point of external auditory meatus; Point Or (orbital): most inferior point of infraorbital margin; Point Gn (gnathic): unpaired point between the most inferior and the most anterior points of menton of bone contour; Medial Sagittal Plan (Mandibular Sagittal Plane - MSP): plan referent to the union of nasion and basion points, perpendicular to the Frankfurt plan (Po-Or). It was used to evaluate changes in the transversal sense.

Individuals were considered skeletal Class I patients when show a value of ANB angle (angle formed by the insertion of the lines NA and NB, which represents the anteroposterior maxillo-mandibular relationship of jaws) between 0° and 5°.

To evaluate the mandibular asymmetry, the deviation of gnathic point to the medial sagittal plan was considered. Thereunto, both the mandibular asymmetry sides deviation (right and left) were evaluated, as well as the intensity of this asymmetry. When this deviation is localized most to the left side, a positive value is attributed to it, and when this

deviation is localized most to the right side, a negative value. To evaluate the intensity of mandibular asymmetry, individuals with deviation of Gn to the MSP until 2mm were considered light asymmetry patients (relative asymmetry patients). Patients with gnathic deviation from 2 to 5mm were considered with moderate asymmetry. People with gnathic deviation in relation to the medial sagittal plan higher than 5mm were considered severe asymmetry patients. These parameters were adopted following data suggested by other works^{2,3,9} (Figure 1).

Figure 1. Measures evaluated by selection of individuals and for posterior analysis of mandibular asymmetries in patients.



To quantify the method error, 20% of CBCT images were randomly selected and once again measured by the same author (BFG) with a two-week interval, between the first and second evaluation. The intra observer variability was 0.2 mm (+/- 0.1 mm) for the CBCT measurements, according to Dahlberg's formula: $\sqrt{\sum D^2/2N}$.

After data collection, a database was structured to enable application of statistical tests using the software SPSS 20 for Windows.

In order to verify the association between the prevalence of side deviation of mandibular asymmetry and the intensity of this asymmetry about the individuals' gender, the Chi-square test was performed and the level of significance adopted was 5% ($p < 0.05$).

were 250; 92 (36.8%) were male and 158 (63.2%) were female.

The frames 1 and 2 reveal there is not statistically significant difference among the variables gender, side deviation and intensity of mandibular asymmetry.

RESULTS

For the population studied, the average of ANB angle was 2.80° , the total of individuals

Frame 1. Distribution of side deviation occurrence of mandibular asymmetry according with the gender.

	Side.deviation of mandibular asymmetry	
	Right N (%)	Left N (%)
Gender		
Male	40 ^a (43,5%)	52 ^a (56,5%)
Female	66 ^a (41,8%)	92 ^a (58,2%)

Each subscribed letter means a subset of categories of side deviation in which the proportion of columns does not show significant differences among them according with the level of significance 5% ($p < 0.05$).

$X^2 = 0,069^a$; $p = 0,792$ non-significant - $n =$ number of individuals; %percentage

Frame 2 - Distribution of intensity occurrence of mandibular asymmetry according with the gender.

	Intensity of mandibular asymmetry		
	Slight N (%)	Moderate N (%)	Severe N (%)
Gender			
Male	56 ^a (60,9%)	31 ^a (33,7%)	05 ^a (5,4%)
Female	85 ^a (53,8%)	54 ^a (34,2%)	19 ^a (12,0%)

Each subscribed letter means a subset of categories of side deviation in which the proportion of columns does not show significant differences among them according with the level of significance 5% ($p < 0.05$).

$X^2 = 3,150^a$; $p = 0,207$ non-significant - $n =$ number of individuals; %percentage

Mandibular deviation varied from 11.45mm to the right side and until 19.94mm to the left side; 106 (42.4%) individuals presented right deviation and 144 (57.6%) to the left. Thereunto, mandibular deviation occurred most frequently to the left side in

both genders (male 56.5% and female 58.2%), with no statistically significant difference between them ($p = 0.792$).

Regarding to the intensity of mandibular asymmetry, the occurrence of slight, moderate and severe asymmetries in the

total sample was respectively 141 (56.4%), 85 (34%) and 24 (9.6%).

DISCUSSION

The current perspective of orthodontic and orthopedic treatments is linked to the aesthetic; and previous studies reveal that the symmetry presents a definitive and significant influence in the facial look¹⁷⁻¹⁹.

Facial symmetry refers to a state of harmony in which both sides of face are well balanced. On the opposite, the term asymmetry is used when there is an unbalance regarding to the homologous parts component to the dentofacial complex, affecting the proportions among the structures^{10,18}.

In order to evaluate this question, this study analyzed the mandibular asymmetry through cone-beam computed tomography, once nowadays this is the most reliable method of diagnosis and indicated for this aim²⁰.

It was observed that most of the sample (57.6%) presented gnathic deviation to the left, suggesting that the mandible presents bigger dimension in the right side. Regarding to the gender, a very similar proportion was observed for both male and female genders (respectively 56.5% and 58.2%), with no observation of statistically difference.

The results presented in this study corroborate works which assert that the predominant side of mandibular deviation is

the left^{21,22}, although there have been previously reported that this difference between right and left sides does not present statistically significant difference¹⁸. This research still evidenced that mandibular asymmetry was present equally in both genders, as well as observed in previous studies^{3,21,23-27}.

On the other hand, a controversy still remains regarding to the different intensities of mandibular asymmetries. It is fact that the menton is identified as the main characteristic of facial asymmetry. However, the differentiation among slight, moderate and severe asymmetry still remains in discussion.

It is reported that slight facial asymmetry (also known as relative symmetry and non-expressive asymmetry) might be considered normal, and depending on the severity, many times it is not noticed, even by the patient or people who live with him/her. It occurs because clinically symmetric and balanced faces reveal subclinical indexes of asymmetry. In this condition, there is skeletal unbalance, but it can be masked by soft tissues which recover it. Moderate asymmetry may be treated in a compensatory way, both by orthodontics and orthopedics approaches in the adolescence. On the other hand, severe asymmetry compromise concomitantly function and aesthetic for patients, but they can be corrected usually by association of surgical and orthodontic procedures¹⁰.

In this study, slight asymmetry was classified when the gnathic deviation to the medial sagittal plan was from 0 to 2mm. Moderate asymmetry was determined as that what present gnathic deviation from 2 to 5mm, while severe deviation represented that what present gnathic deviation from medial sagittal plan upper 5mm. These values were based on approximated values proposed by previous studies^{2,3,28}.

In the sample evaluated, it was evidenced the most of individuals presented relative symmetry (slight asymmetry), corresponding to 56.4% of individuals. Moderate and severe symmetries represented respectively 34% and 9.6% of individuals.

Regarding to the gender, it was observed percentage values of prevalence of asymmetries according with intensity (slight, moderate and severe, respectively), in 60.9%, 33.7% and 5.4% for male and 53.8%, 34.2% and 12% for female; once again there is no statistically significant difference ($p=0.207$) between them.

In this context, it is observed that more studies are necessary to evaluate the prevalence of mandibular asymmetry in the several sagittal patterns of facial growth, as well as determine skeletal components associated to different intensity of mandibular asymmetries.

CONCLUSION

In the sample evaluated in this study, most of individuals evaluated presented mandibular deviation to the left side. Besides, slight asymmetry was prevalent, followed by moderate and severe ones. Regarding to the sexual dimorphism, both deviation and intensity of mandibular asymmetry did not present preference according to the gender.

REFERENCES

1. Bishara SE, Jorgensen GJ, Jakobsen JR. Changes in facial dimensions assessed from lateral and frontal photographs. Part I-Methodology. *Am J Orthod Dentofacial Orthop.* 1995;108(4):389-393.
2. Katsumata A, Fujishita M, Maeda M, Ariji Y, Ariji E, Langlais RP. 3D-CT evaluation of facial asymmetry. *Oral Surgery, Oral Medicine, Oral Pathology, Oral Radiology, and Endodontology* 2005;99(2):212-220.
3. Ramirez-Yañez GO, Stewart A, Franken, E, Campos, K. Prevalence of mandibular asymmetries in growing patients. *The European Journal of Orthodontics* 2011;33(3):236-242.
4. Silva NCFD, Aquino ERBD, Mello KCFR, Mattos JNR, Normando D. Orthodontists' and laypersons' perception of mandibular asymmetries. *Dental Press Journal of Orthodontics* 2011;16(4):38-e1.
5. Severt TR, Proffit WR. The prevalence of facial asymmetry in the dentofacial deformities population at the University of North Carolina. *The International journal of adult orthodontics and orthognathic surgery* 1997;12(3):171.

6. Kim SJ, Lee KJ, Lee SH, Baik HS. Morphologic relationship between the cranial base and the mandible in patients with facial asymmetry and mandibular prognathism. *Am J Orthod Dentofacial Orthop* 2013;144:330-40.
7. Yáñez-Vico RM, Iglesias-Linares A, Torres-Lagares D, Gutiérrez-Pérez JL, Solano-Reina E. Three-dimensional evaluation of craniofacial asymmetry: an analysis using computed tomography. *Clinical oral investigations* 2011;15(5):729-736.
8. You KH, Lee KJ, Lee SH, Baik HS. Three-dimensional computed tomography analysis of mandibular morphology in patients with facial asymmetry and mandibular prognathism. *Am J Orthod Dentofacial Orthop* 2010;138(5):540-e1.
9. Maeda M, Katsumata A, Arijji Y, Muramatsu A, Yoshida K, Goto S et al. 3D-CT evaluation of facial asymmetry in patients with maxillofacial deformities. *Oral Surgery, Oral Medicine, Oral Pathology, Oral Radiology, and Endodontology* 2006;102(3):382-390.
10. Masuoka N, Momoi Y, Arijji Y, Nawa H, Muramatsu A, Goto S, et al. Can cephalometric indices and subjective evaluation be consistent for facial asymmetry? *Angle Orthod.* 2005;75(4):651-5.
11. Cevidanes LH, Alhadidi A, Paniagua B, Styner M, Ludlow J, Mol A et al. Three-dimensional quantification of mandibular asymmetry through cone-beam computerized tomography. *Oral Surgery, Oral Medicine, Oral Pathology, Oral Radiology, and Endodontology* 2011;111(6):757-770.
12. Fong JH, Wu HT, Huang MC, Chou YW, Chi LY, Fong Y, et al. Analysis of facial skeletal characteristics in patients with chin deviation. *J Chin Med Assoc.* 2010;73(1):29-34.
13. Haraguchi S, Takada K, Yasuda Y. Facial asymmetry in subjects with skeletal Class III deformity. *Angle Orthod.* 2002;72(1):28-35.
14. Kusayama M, Motohashi N, Kuroda T. Relationship between transverse dental anomalies and skeletal asymmetry. *Am J Orthod Dentofacial Orthop.* 2003;123(3):329-337.
15. Hwang HS, Hwang CH, Lee KH, Kang BC. Maxillofacial 3-dimensional image analysis for the diagnosis of facial asymmetry. *Am J Orthod Dentofacial Orthop.* 2006;130(6):779-785.
16. Garib DG, Raymundo JR, Raymundo MV, Raymundo DV, Ferreira SN. Tomografia computadorizada de feixe cônico (cone beam): entendendo este novo método de diagnóstico por imagem com promissora aplicabilidade na Ortodontia. *Dental Press Ortodon Ortop Facial.* 2007;12(2):139-56.
17. Hönn M, Göz G. The ideal of facial beauty: a review. *Journal of Orofacial Orthopedics/Fortschritte der Kieferorthopädie* 2007;68(1):6-16.
18. Peck S, Peck L, Kataja M. Skeletal asymmetry in esthetically pleasing faces. *Angle Orthod.* 1991;61(1):43-8.3.
19. Rhodes G, Sumich A, Byatt G. Are average facial configurations attractive only because of their symmetry? *Psychological Science* 1999;10(1):52-58.
20. Moraes MEL, Hollender LG, Chen CSK, Moraes LC, Balduccio I. Evaluating craniofacial asymmetry with digital cephalometric images and cone-beam computed tomography. *Am J Orthod Dentofacial Orthop* 2011;139:e523-e531
21. Haraguchi S, Iguchi Y, Takada K. Asymmetry of the face in orthodontic patients. *Angle Orthod.* 2008;78(3):421-426.

22. Kim EJ, Palomo JM, Kim SS, Lim HJ; Lee KM, Hwang HS Maxillofacial characteristics affecting chin deviation between mandibular retrusion and prognathism patients *Angle Orthod.* 2011;81:988–993.

23. Sezgin OS, Celenk P, Arici S. Mandibular asymmetry in different occlusion patterns. *Angle Orthod.* 2007;77(5):803-7.

24. Kurt G, Uysal T, Sisman Y, Ramoglu SI. Mandibular asymmetry in Class II subdivision malocclusion. *Angle Orthod.* 2008;78(1):32-7.

25. Ferrario VF, Sforza C, Miani Jr A, Serrao G. A three-dimensional evaluation of human facial asymmetry. *J Anat.* Feb 1995;186(Pt 1):103–110.

26. Azevedo AR, Janson G, Henriques JF, Freitas MR. Evaluation of asymmetries between subjects with Class II subdivision and apparent facial asymmetry and those with normal occlusion. *Am J Orthod Dentofacial Orthop.* 2006;129(3):376-83.

27. Hwang HS, Yuan D, Jeong KH, Uhm GS, Cho JH, Yoon SJ. Three-dimensional soft tissue analysis for the evaluation of facial asymmetry in normal occlusion individuals. *Korean J Orthod.* 2012;42(2):56-63.

28. Sievers MM, Larson BE, Gaillard PR, Wey A. Asymmetry assessment using cone beam CT. A Class I and Class II patient comparison. *Angle Orthod.* 2012;82(3):410-7.